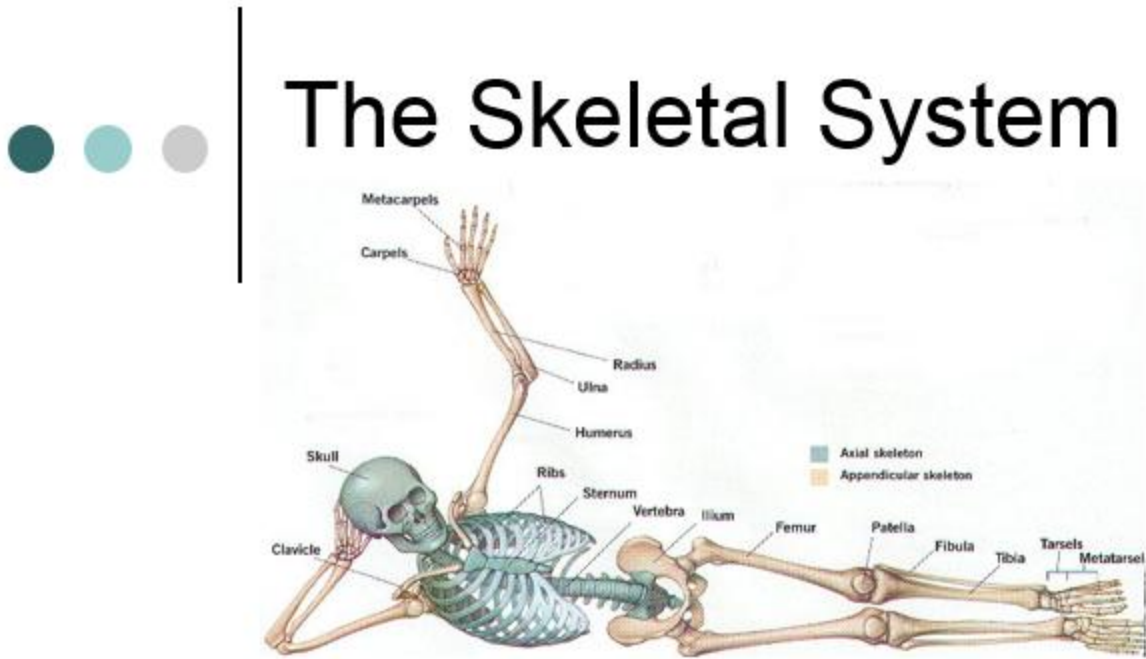


Name _____ Period _____

Medical Terminology

Chapter 2



Labeling Activities

Labeling the Long Bone

(Label & Color)

Using the following terms:

Red Marrow (red)

Medullary Cavity (black)

Endosteum (orange)

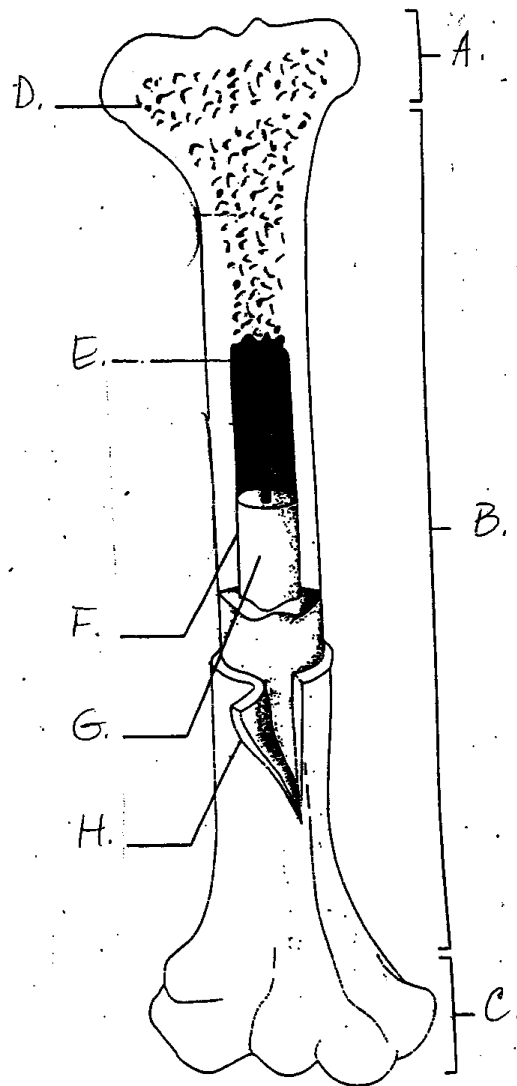
Yellow Marrow (yellow)

Periosteum (green)

Proximal Epiphysis (purple)

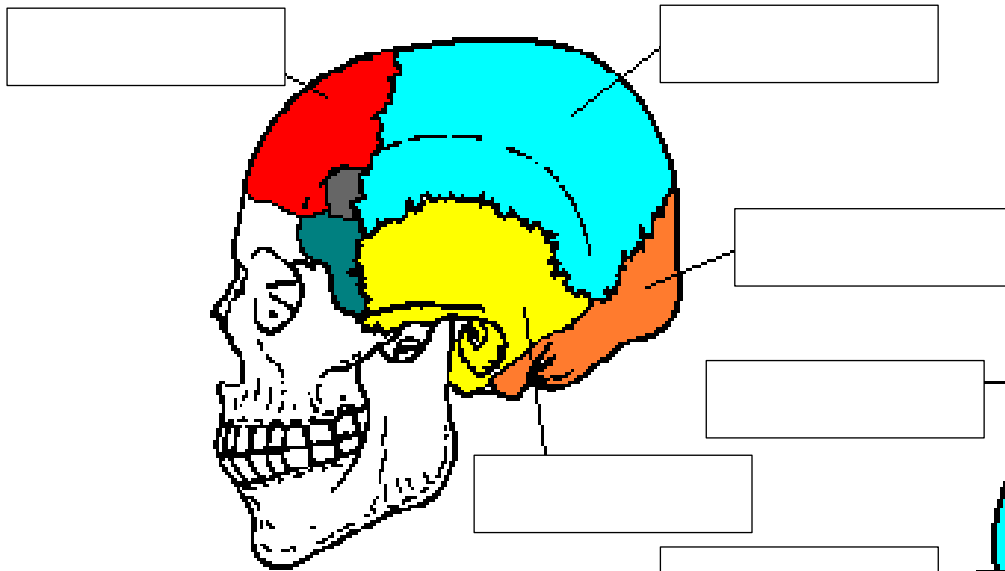
Diaphysis (pink)

Distal Epiphysis (blue)

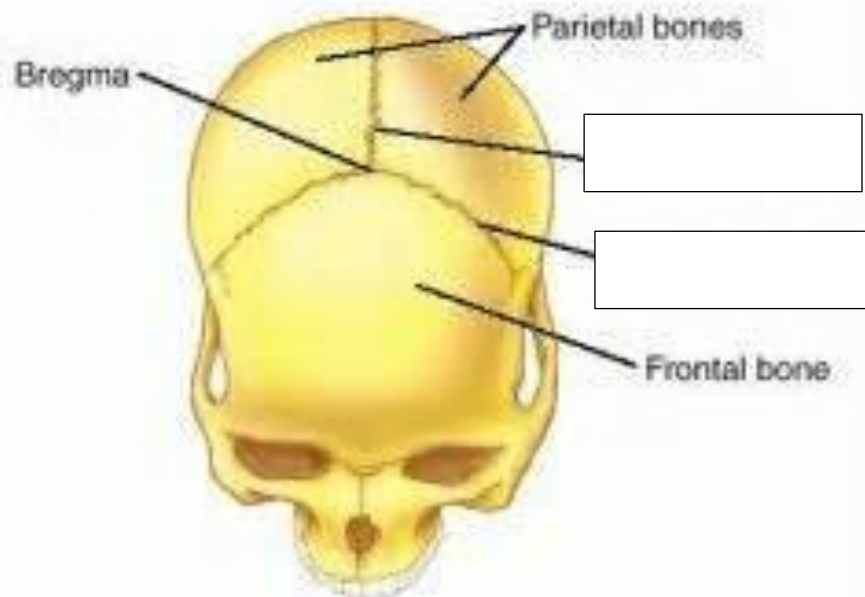
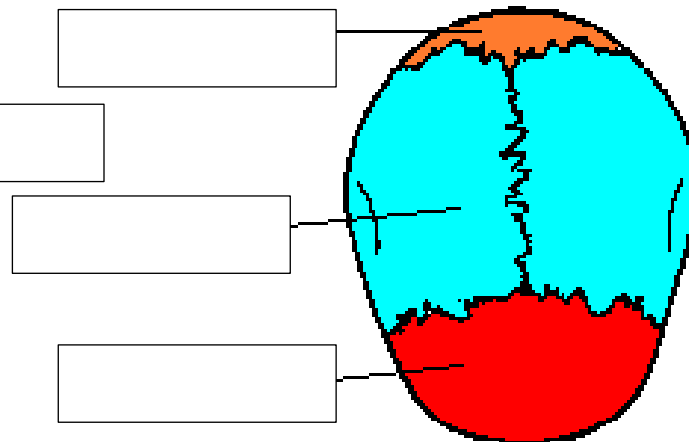


Bones/Sutures of Skull

Side View



Top View



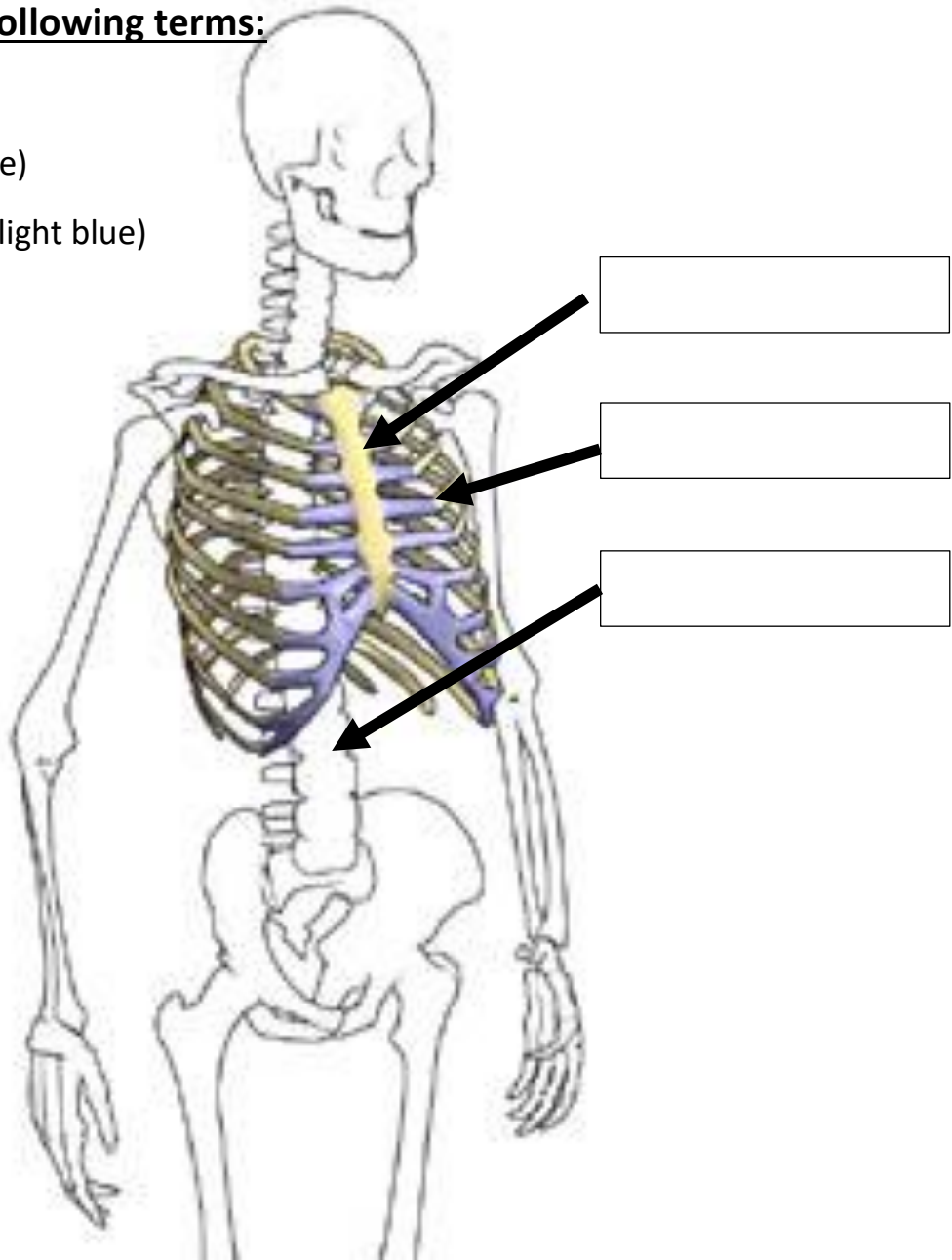
Sternum/Ribs/Vertebral Column

Label using the following terms:

Sternum (yellow)

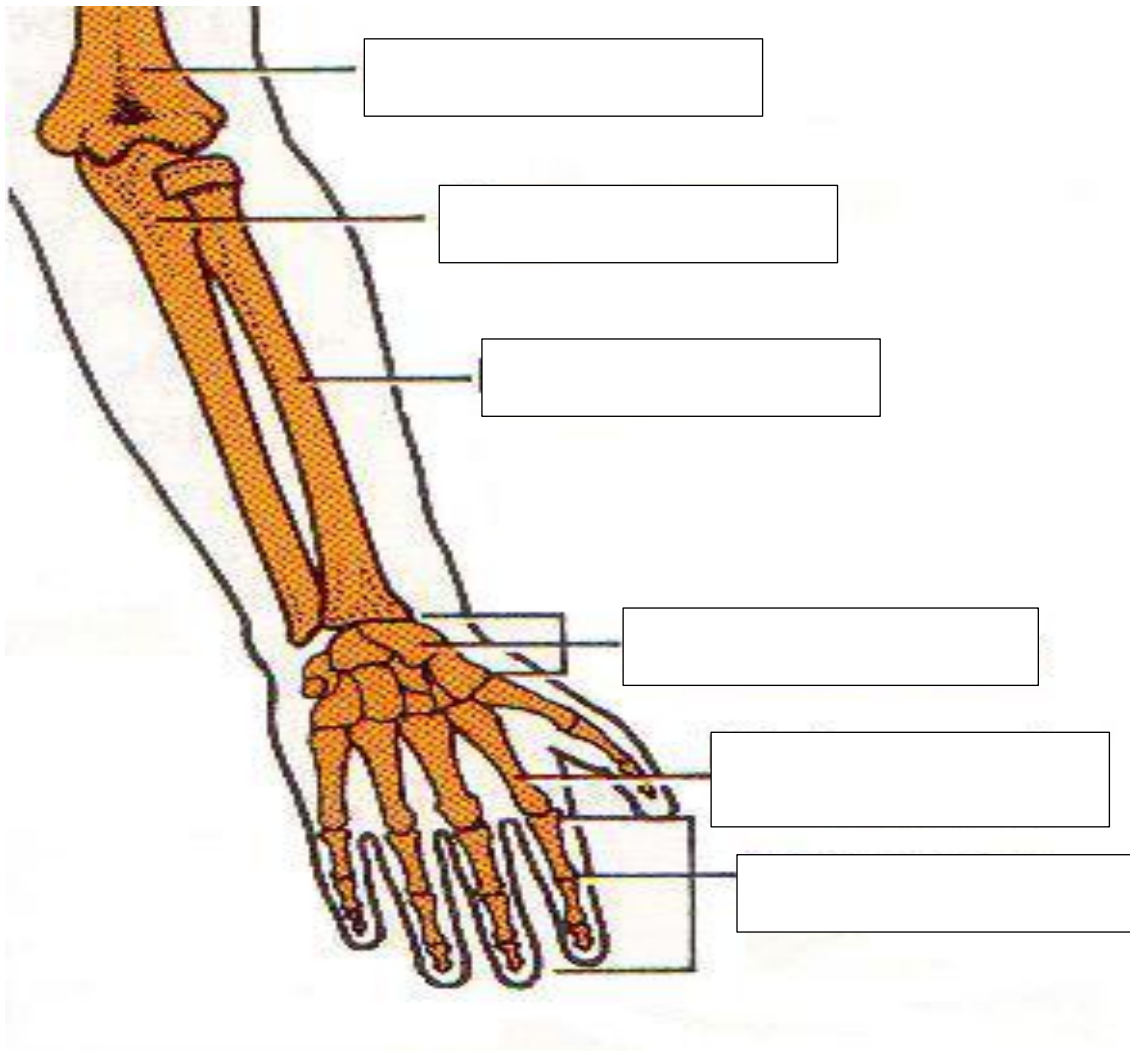
Ribs/Costals (purple)

Vertebral column (light blue)



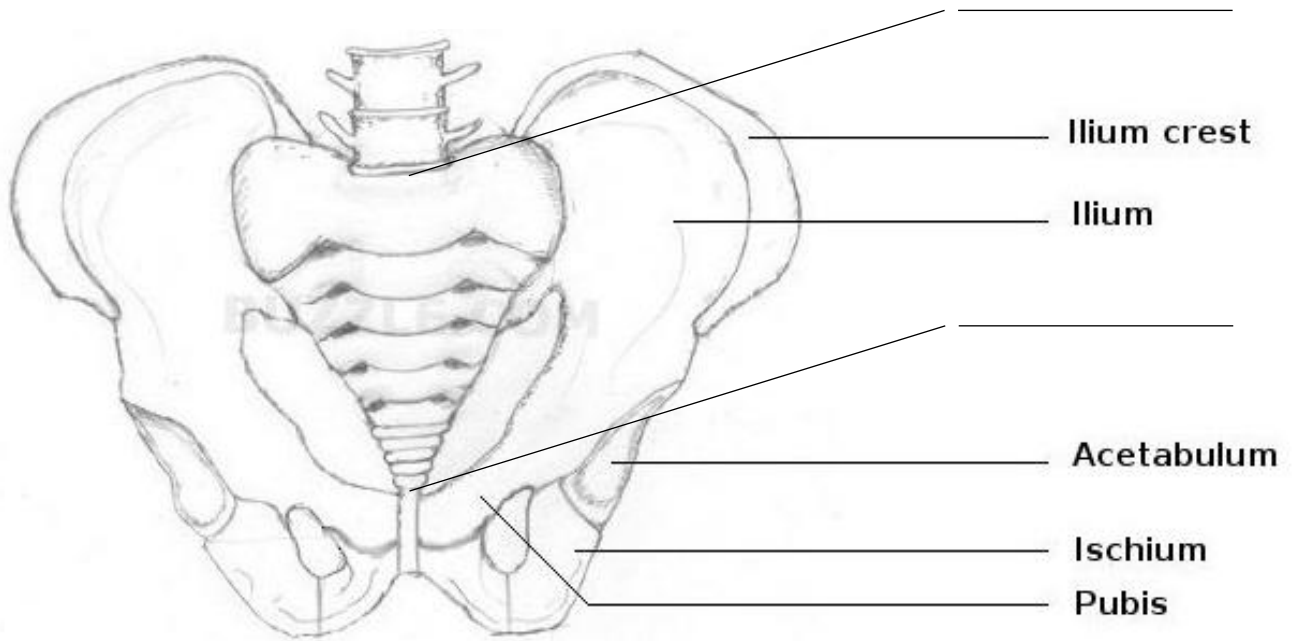
Color & Label!!!

Bones of Arms/Wrist/Hands



****Copy the labels from the powerpoint****

Pelvic Girdle



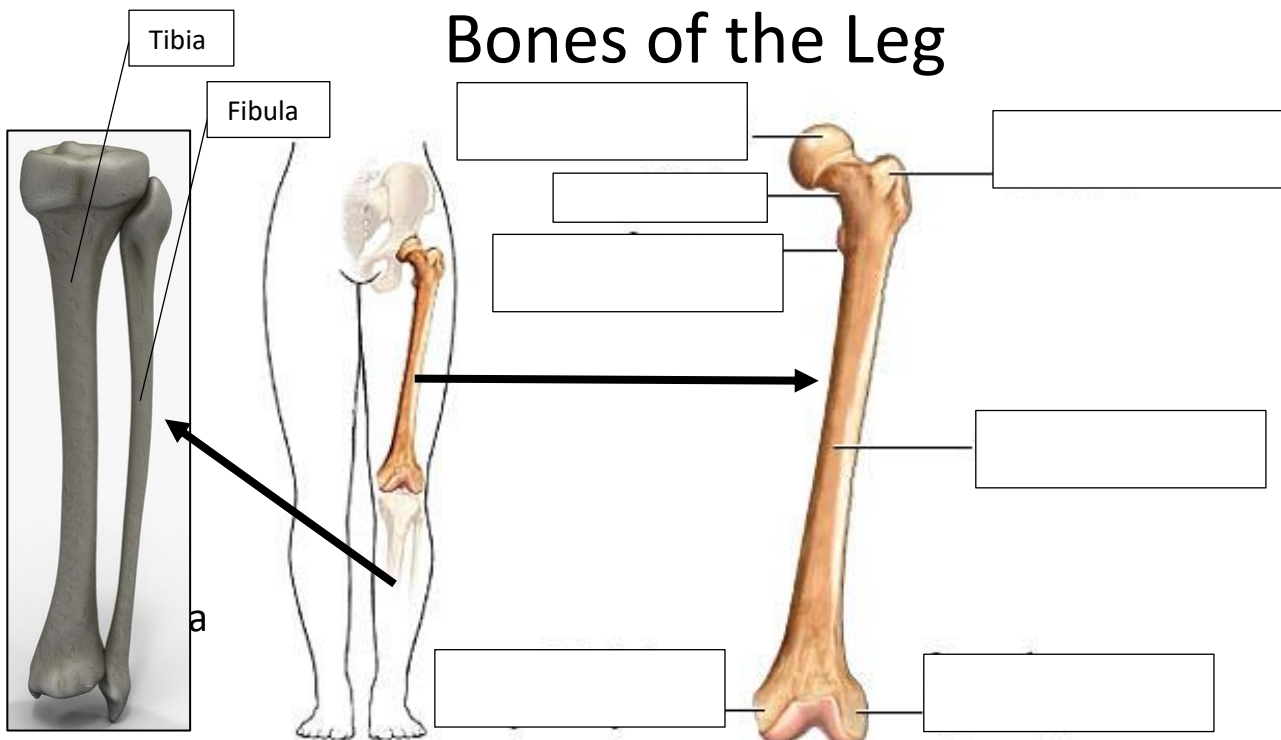
Add these labels (above):

Sacrum (pink)

Coccyx (red)

Pubic Symphysis (orange)

Bones of the Leg



Bones of the Foot

Label/Color the Following:

- **Malleolus** (ankle bone)- purple
- **Calcaneus**- orange
- **Metatarsals**- yellow
- **Phalanges**- blue
- **Tibia**- pink
- **Cuneiforms**- green

