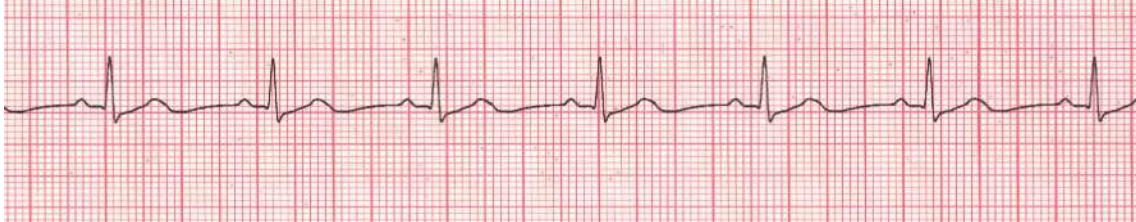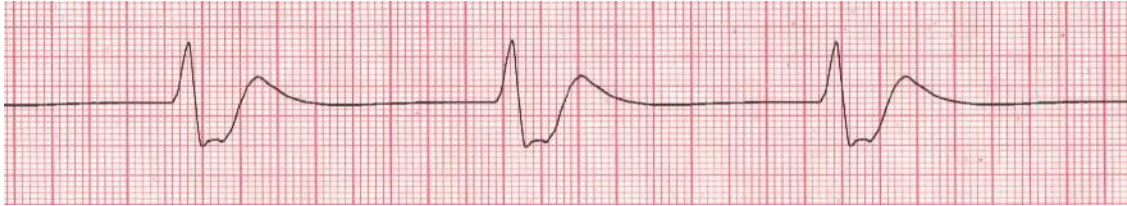


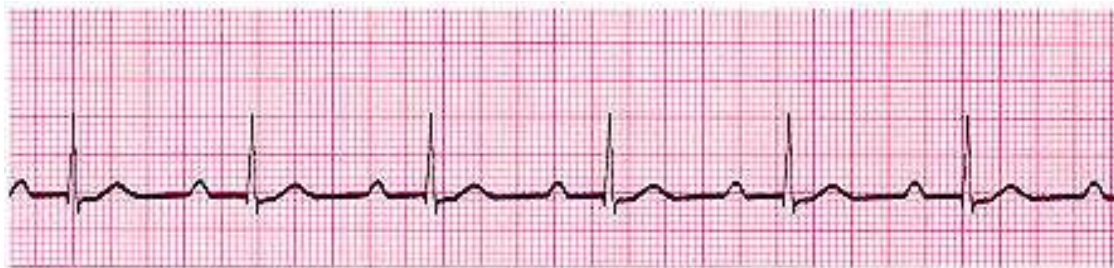1. Irregular or Regular? Rate:



2. Irregular or Regular? Rate:

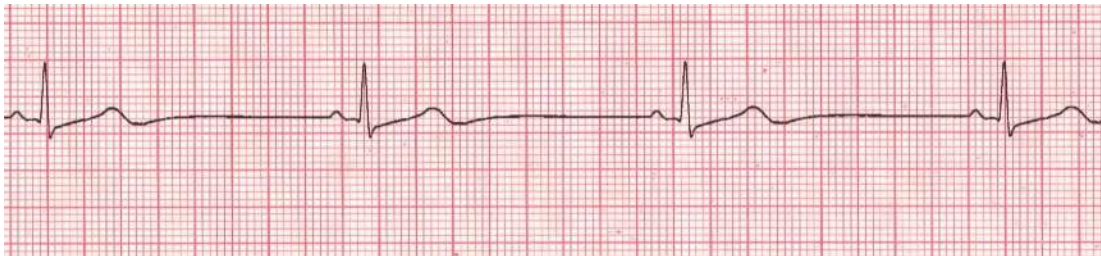

3. Irregular or Regular? Rate:

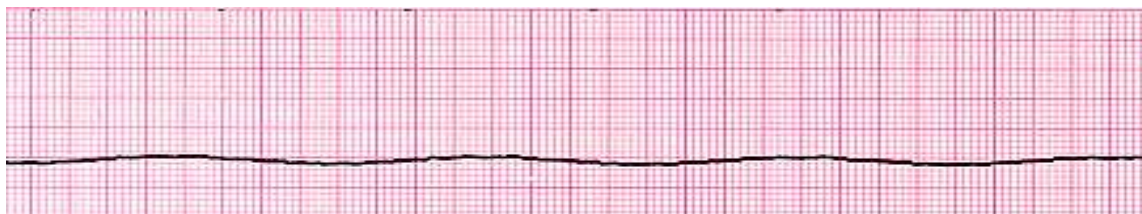

1st Degree Heart Block

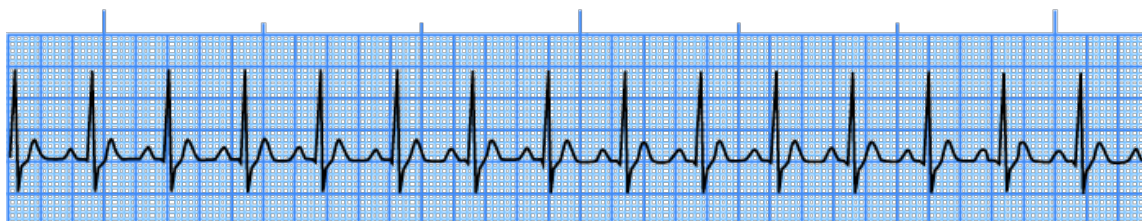
4. Irregular or Regular? Rate:



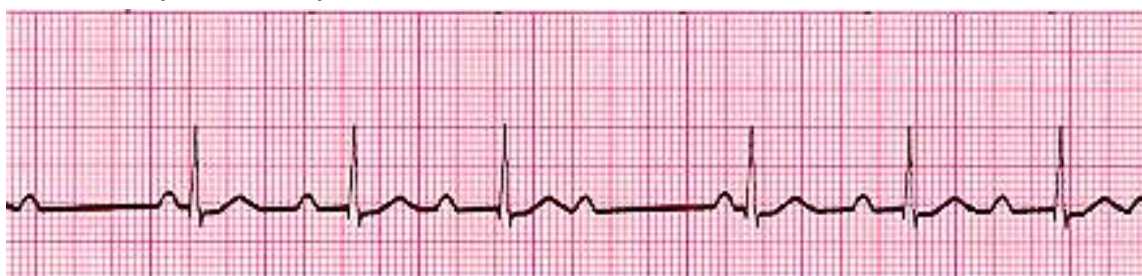5. Irregular or Regular? Rate:



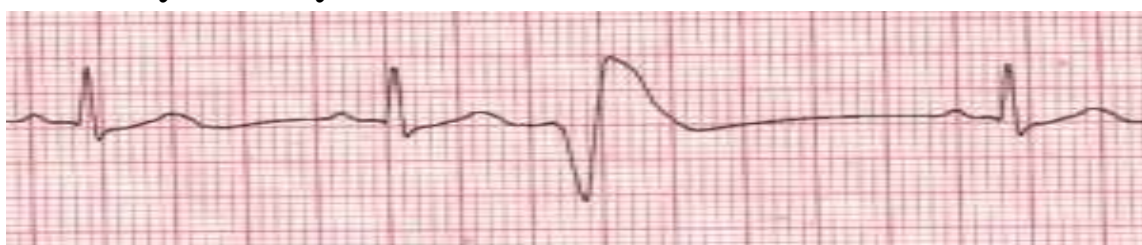6. Irregular or Regular? Rate:



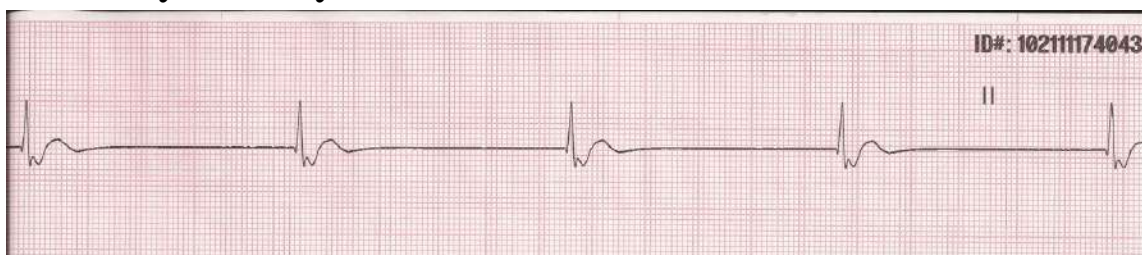7. Irregular or Regular? Rate:



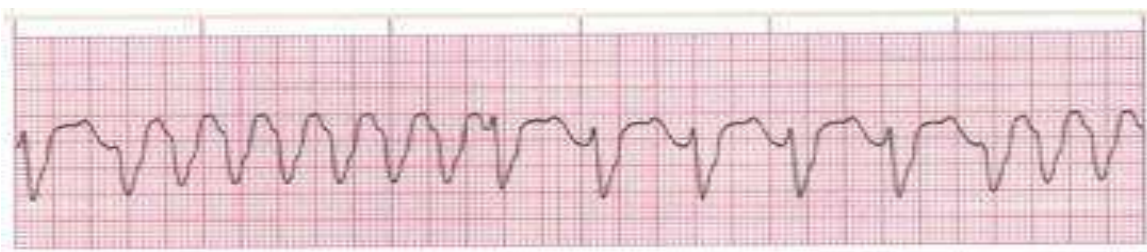8. Irregular or Regular? Rate:



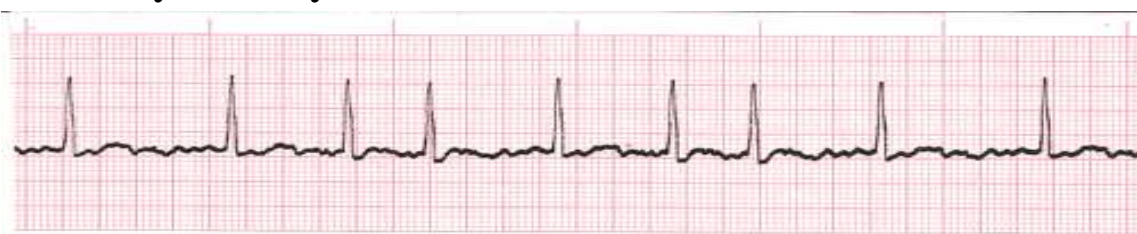9. Irregular or Regular? Rate:



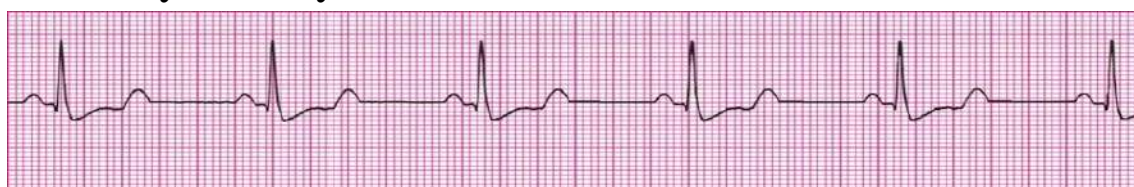10. Irregular or Regular? Rate:



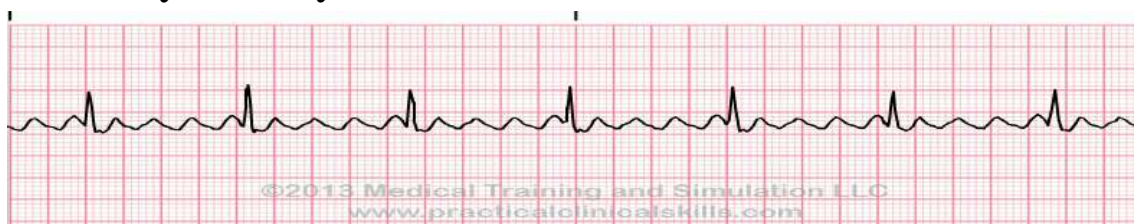11. Irregular or Regular? Rate:



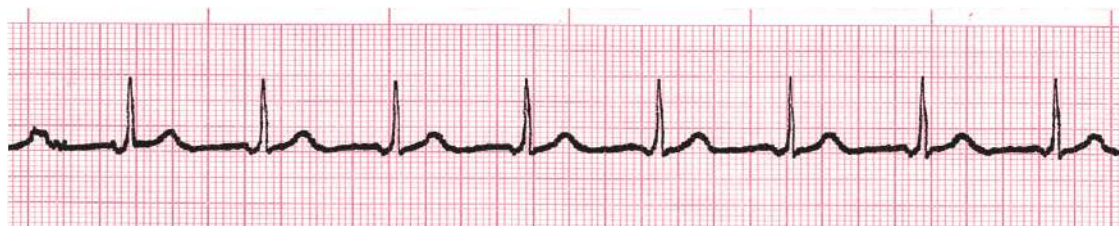12. Irregular or Regular? Rate:



13. Irregular or Regular? Rate:

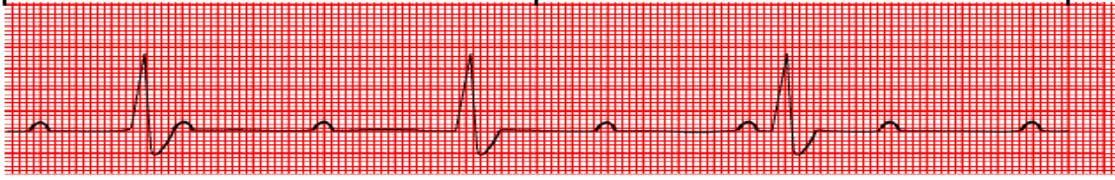


14. Irregular or Regular? Rate:



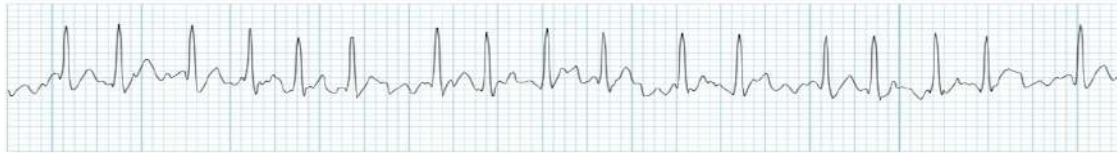
15. Irregular or Regular? Rate:

THIRD DEGREE (COMPLETE) AV BLOCK

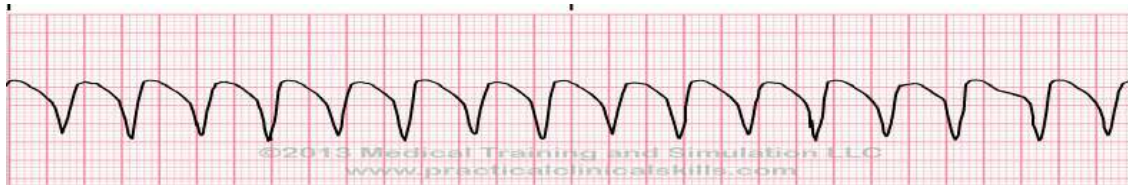


HEALTH INTERACTIVE © 1999 - WWW.RNCEUS.COM

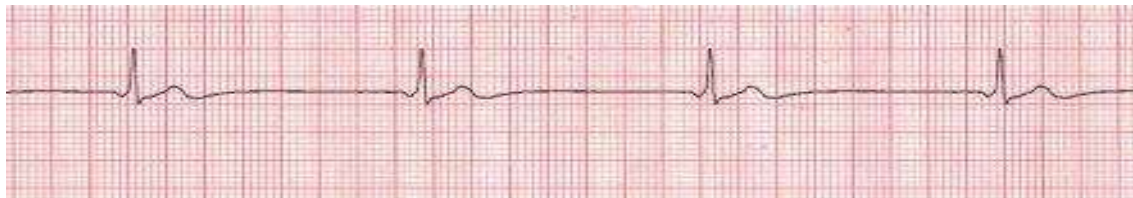16. Irregular or Regular? Rate:



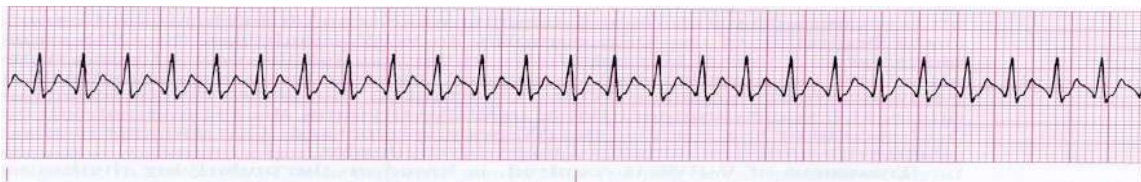17. Identify the heart rhythm represented by the following EKG strip.



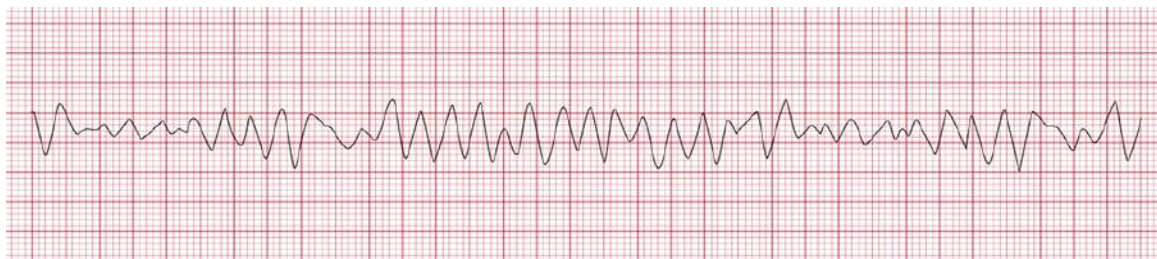
18. Identify the heart rhythm represented by the following EKG strip.



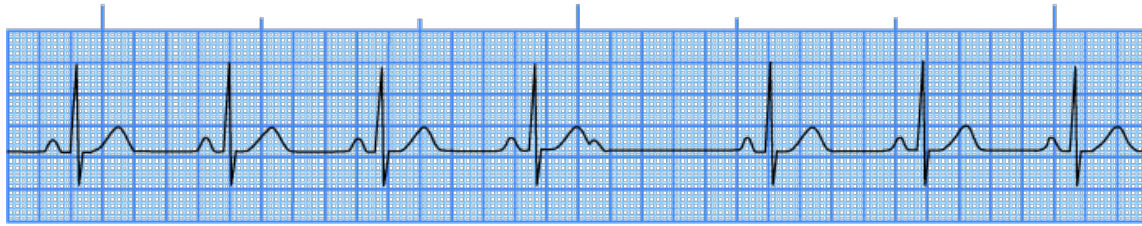
19. Identify the heart rhythm represented by the following EKG strip.



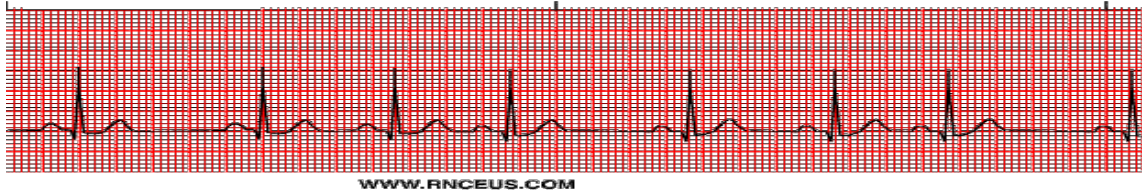
20. Identify the heart rhythm represented by the following EKG strip.



21. Identify the heart rhythm represented by the following EKG strip.



22. Identify the heart rhythm represented by the following EKG strip.



Word Bank

NORMAL SINUS RHYTHM	SINUS TACHYCARDIA	ATRIAL FIBRILLATION
SINUS BRADYCARDIA	SINUS ARRHYTHMIA	ATRIAL FIBRILLATION WITH RAPID VENTRICULAR RESPONSE
ATRIAL FLUTTER	PREMATURE ATRIAL COMPLEX	SUPRAVENTRICULAR TACHYCARDIA
JUNCTIONAL RHYTHM	JUNCTIONAL BRADYCARDIA	ACCELERATED JUNCTIONAL RHYTHM
IDIOVENTRICULAR RHYTHM	POLYMORPHIC VENTRICULAR TACHYCARDIA	VENTRICULAR TACHYCARDIA
VENTRICULAR FIBRILLATION	ASYSTOLE	NORMAL SINUS RHYTHM WITH PREMATURE VENTRICULAR COMPLEX
1ST DEGREE HEART	2ND DEGREE HEART	2ND DEGREE HEART

BLOCK	BLOCK, TYPE 1	BLOCK, TYPE 2
3RD DEGREE HEART BLOCK		