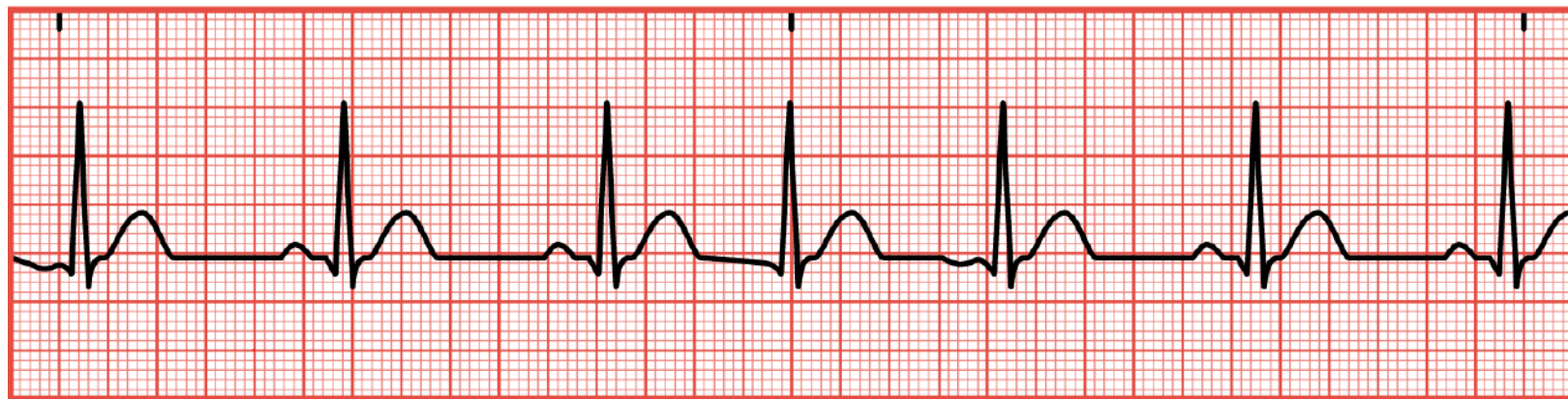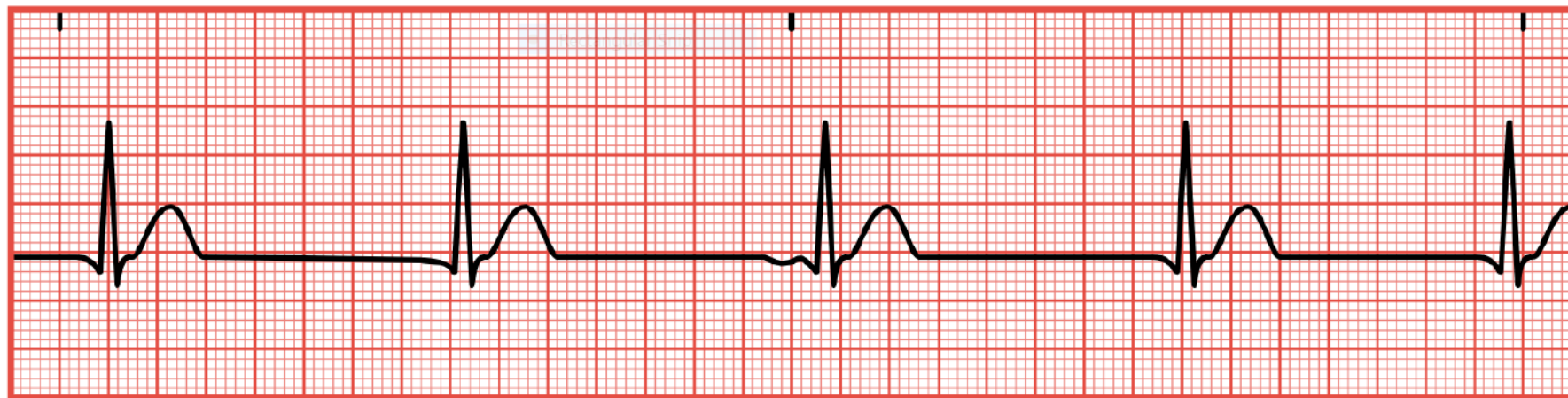


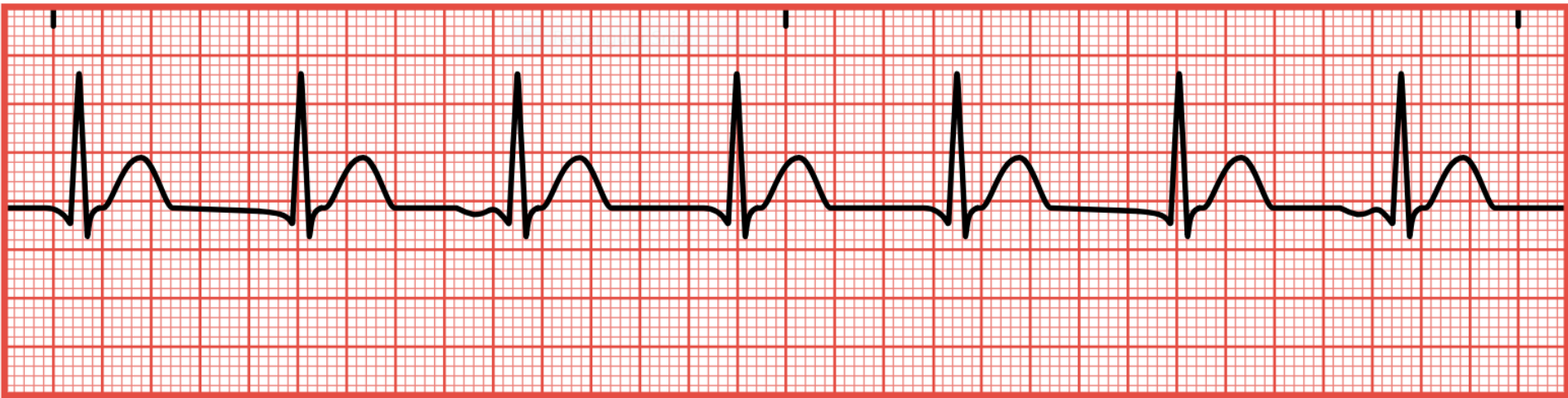


Sinus Rhythm with a
premature junctional complex
(PJC); Vent rate of 40bpm



Junctional Escape rhythm

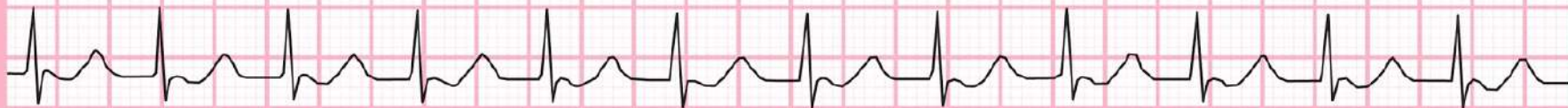Inverted or absent P waves; HR is between 40-60 bpm



Accelerated Junctional Rhythm

No P waves or inverted; 60-100 bpm; pt. Will likely not experience signs/symptoms

Lead II

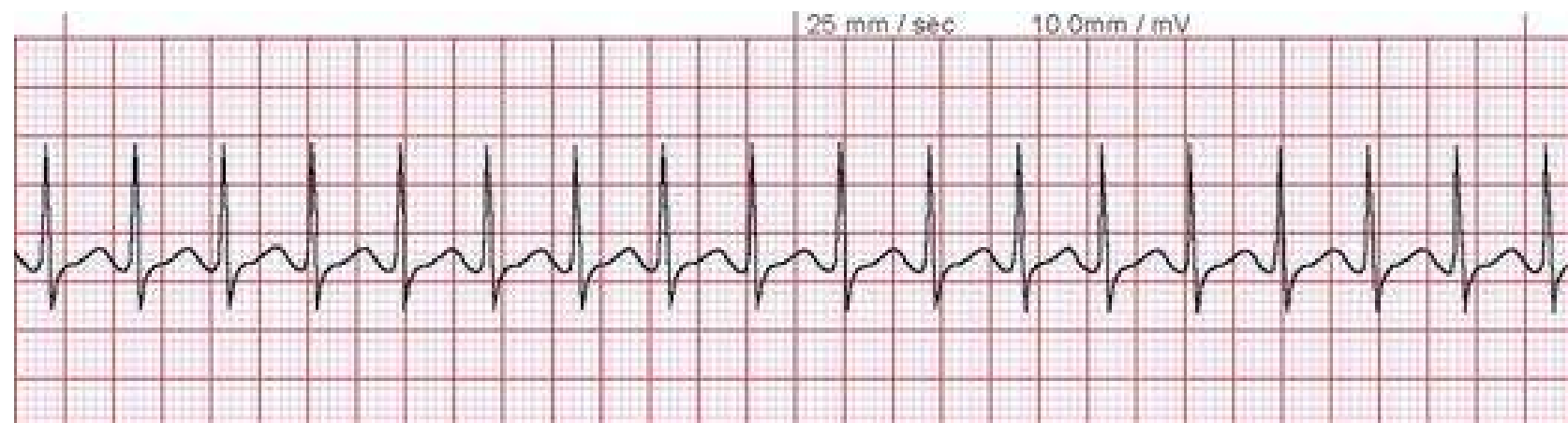


25mm/sec 10mm/mV

© Jason Winter 2016 - @ ECG Educator

Junctional Tachycardia

No P waves or inverted; greater than 100-150 bpm; pt. may experience symptoms of palpitations or fluttering



Supra-ventricular tachycardia (SVT)