

## The Skeletal System

### Functions of The Skeletal System:

- 1.
- 2.
- 3.
- 4.
- 5.

### Structures of The Skeletal System:

- 1.
- 2.
- 3.
- 4.
- 5.


### The Structures of Bones:

Form of connective tissue and is almost the hardest tissue in the body.

**Tissues of Bone** - It may be hard and dense, but is also a living structure that changes and is capable of healing itself.

| Tissues of a Bone |  |
|-------------------|--|
|                   | Tough fibrous tissue that forms the outermost covering of bone   |
|                   | Hard, dense, and very strong bone that forms the outer layer of the bones.   |
|                   | Lighter and not as strong as compact bone, it is commonly found in the ends and inner portions of long bone; house the red bone marrow |
|                   | Located in the shaft of a long bone and surrounded by compact bone; lined with endosteum and contains yellow bone marrow               |

*\*Place bone drawing here*



## The Skeletal System

|  |   |
|--|---|
|  | <ul style="list-style-type: none"> <li>• located in the spongy bone</li> <li>• is hematopoietic</li> <li>• manufactures               <ul style="list-style-type: none"> <li>○</li> <li>○</li> <li>○ megakaryocytes (produce thrombocytes)</li> </ul> </li> </ul> |
|  | Means pertaining to the formation of blood cells  |
|  | <ul style="list-style-type: none"> <li>• located in the medullary cavity</li> <li>• composed of fat cells</li> <li>•</li> </ul>   |

### Cartilage –

|                 |  |
|-----------------|--|
|                 | <ul style="list-style-type: none"> <li>• smooth rubbery blue-white connective tissue</li> <li>• acts as a shock absorber between bones</li> <li>• more elastic than bone</li> <li>• makes up the flexible parts of the skeleton such as tip of nose and outer ear</li> </ul> |
|                 | <ul style="list-style-type: none"> <li>• covers the surfaces of bones that form joints</li> <li>• make smooth joint movement possible</li> <li>• protect the bones from rubbing against each other</li> </ul>  |
| <b>Meniscus</b> | <ul style="list-style-type: none"> <li>•</li> </ul>  |

### Anatomic Landmarks of a Bone –

|                  |   |
|------------------|---|
| <b>Diaphysis</b> | <ul style="list-style-type: none"> <li>•</li> </ul>   |
|                  | <ul style="list-style-type: none"> <li>• covered with articular cartilage</li> <li>• wide end of a long bone</li> </ul> |
|                  | end of the bone that is located nearest to the midline of the body  |
|                  | end of the bone that is located farthest away from the midline of the body  |
|                  | opening in the bone in which blood vessels, nerves and ligaments pass through   |
| <b>Process</b>   | <ul style="list-style-type: none"> <li>•</li> </ul>   |

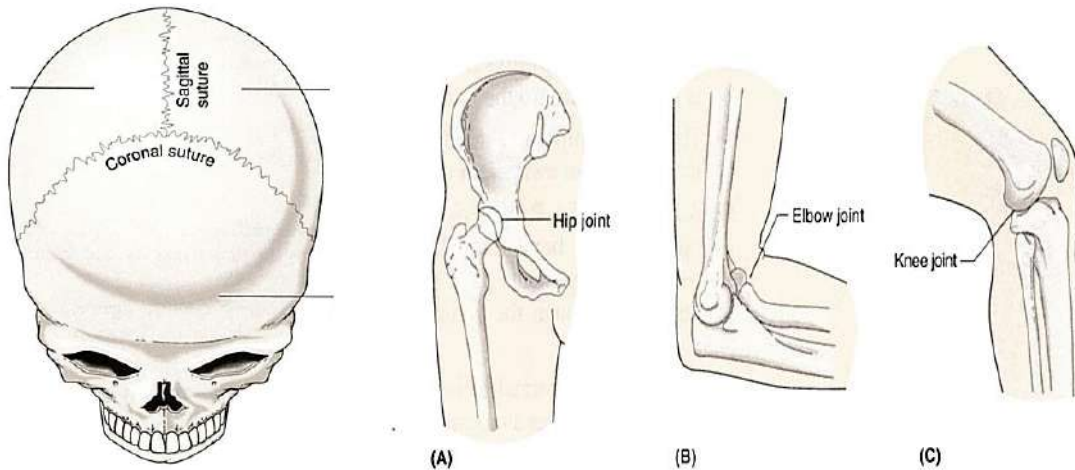
### Joints:

## The Skeletal System

### Articulations –

### **Types of Joints –**

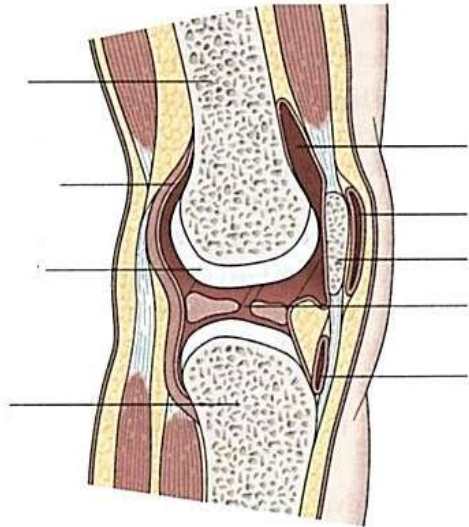
|  |  |
|--|--|
|  | <ul style="list-style-type: none"> <li>• jagged line where bones join and form a joint that doesn't move</li> <li>• At birth, babies have fontanel where the sutures between the frontal and parietal bones have not closed yet</li> </ul>         |
| <b>Symphysis<br/>(cartilaginous joint)</b> | <ul style="list-style-type: none"> <li>•</li> </ul>  |
| <b>Synovial Joints</b>                     | <ul style="list-style-type: none"> <li>• <ul style="list-style-type: none"> <li>○ ball and socket - allow a wide range of movement in many directions</li> <li>○ hinge - allow movement primarily in one direction or plane</li> </ul> </li> </ul> |



### **Structures of Synovial Joints –**

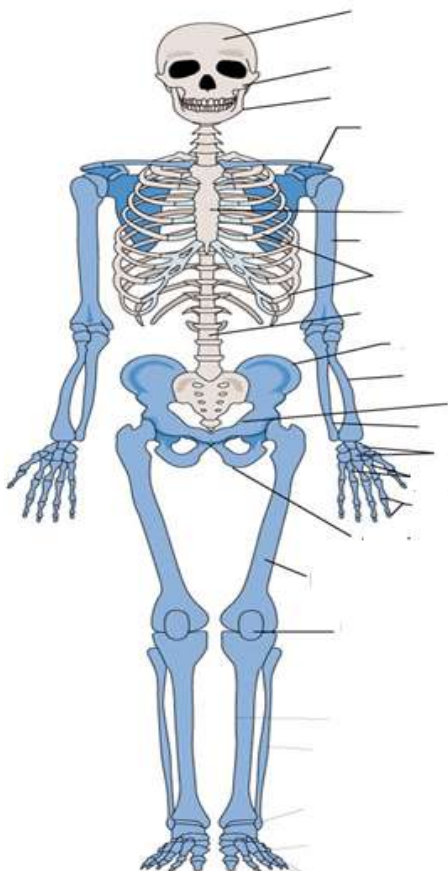
|                       |   |
|-----------------------|---|
| <b>Ligaments</b>      | <ul style="list-style-type: none"> <li>•</li> </ul>   |
|                       | <ul style="list-style-type: none"> <li>• lines the fibrous capsule that surround synovial joints</li> <li>• secretes synovial fluid</li> </ul>                                |
| <b>Synovial Fluid</b> | <ul style="list-style-type: none"> <li>•</li> </ul>   |
|                       | <ul style="list-style-type: none"> <li>• fibrous sac lined with synovial membrane</li> <li>• acts a cushion to ease movement in areas that are subject to friction</li> </ul> |

## The Skeletal System



### The Skeleton:

Consists of 206 bones as an adult.



\_\_\_\_\_ - 80 bones

- protects major organs of the nervous, respiratory, and circulatory systems

- 

- consists of the:

- Skull
- Spinal Column
- Ribs
- Sternum

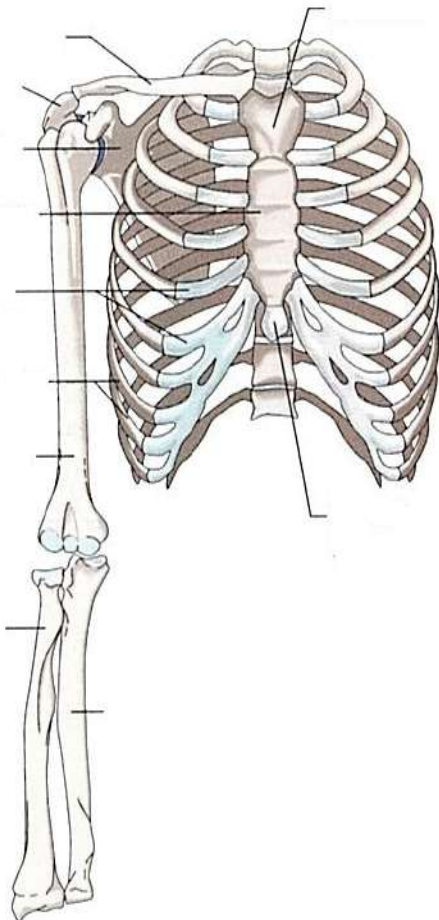
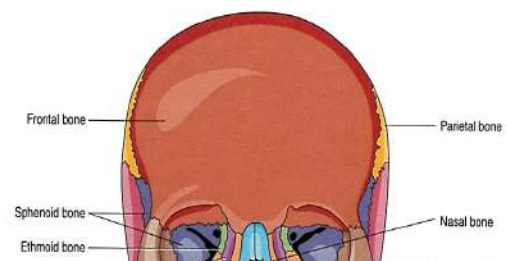
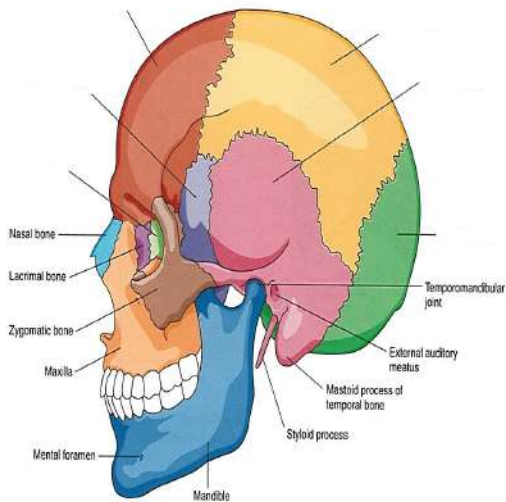
\_\_\_\_\_ - 126 bones

- makes body movement possible
- protects the organs of digestion, excretion and reproduction
- organized into
  - upper extremities - shoulders, arms, forearms, wrists and hands
  - lower extremities - hips, thighs, ankles and feet

### **Bones of the Skull -**

## The Skeletal System

- **Bones of the Cranium** - Portion of the skull that encloses the brain



- Frontal bone –
- Parietal bone -
- Occipital bone -
- Temporal bone –
- Sphenoid bone -
- Ethmoid bone -
- Auditory Ossicles –
- External Auditory Meatus -
- **Bones of the Face** -
- Zygomatic bones –
- Maxillary bones –
- Palatine bones -
- Lacrimal bones - part of the orbit at the inner angle of the eye
- Inferior conchae - form part of the interior of the nose
- Vomer bone - base for the nasal septum
- Mandible –
- Hyoid bone -

## Thoracic Cavity, Ribs, and Sternum -

## The Skeletal System

- \_\_\_\_\_ - consists of the ribs, sternum, and thoracic vertebrae
- Ribs -
  - \_\_\_\_\_ (ribs) that connect posteriorly to the thoracic vertebrae
  - Pairs 1-7 attach anteriorly to the sternum; true ribs
  - Pairs 8-10 attach anteriorly to cartilage that joins with the sternum; false ribs
  - Pairs 11 & 12 are called the floating ribs; no anterior attachment
- \_\_\_\_\_ - forms the middle of the front of the rib cage
  - Manubrium - upper portion
  - Body - middle portion
  - Xiphoid process - lower portion

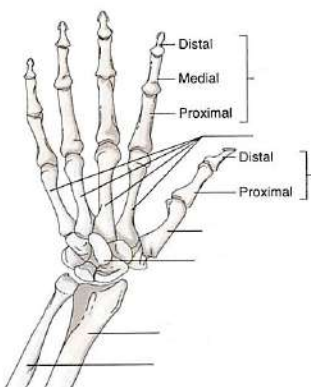
**Shoulder (pectoral girdle)** - shoulder girdle supports the arms and hands

- \_\_\_\_\_ - connects the sternum to the scapula
- \_\_\_\_\_ - extension of the scapula that forms the high point of the shoulder

### Arms –

- Humerus –
- Radius –
- Ulna –
- Olecranon process (funny bone) - large projection on the upper end of the ulna; point of the elbow

### Wrist and Hands –



- Carpals –
- Metacarpals –
- Phalanges -
  - each finger has 3 bones - distal, medial, proximal
  - thumb has 2 - distal and proximal

# The Skeletal System

## Spinal Column –

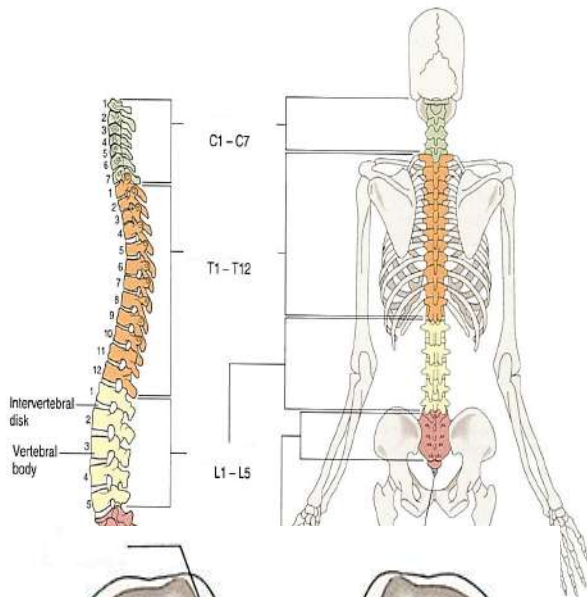
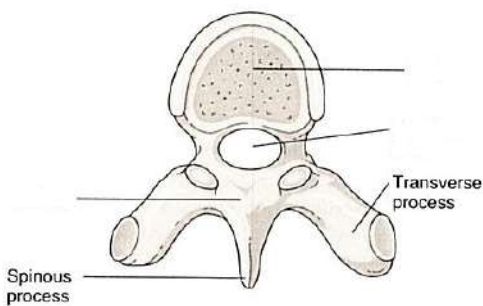
- Vertebral column
- 
- Function is to support the head and body and to protect the spinal column

## Structures of the vertebrae -

- Body solid anterior portion of each vertebrae
- Lamina - posterior portion of a vertebra
- Vertebral Foramen - opening in the middle of the vertebra; allows the spinal cord to pass through

## Types of Vertebrae –

- \_\_\_\_\_ - the first set of seven vertebrae that forms the neck; C1 - C7
- 
- \_\_\_\_\_ - second set of 12 vertebrae;
  - form the outward curve of the spine
  - T1-T12
- \_\_\_\_\_ - third set of vertebrae
  - L1 - L5
  - Largest and strongest
  - form the inward curve of the spine

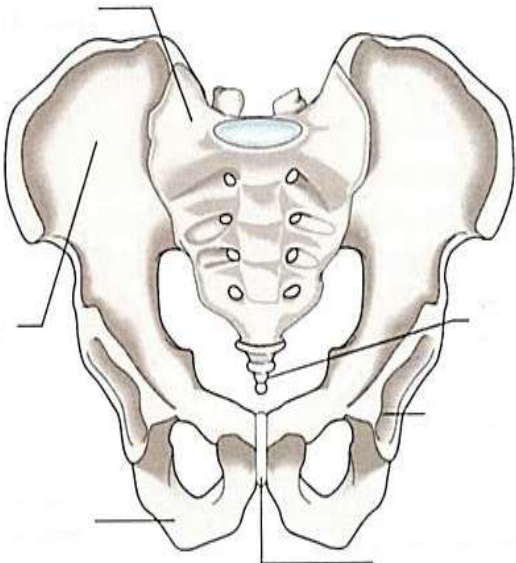


## Intervertebral Disks –

- made of cartilage
- separate and cushion
- act as shock absorbers
- allow for movement

## Sacrum –

- slightly curved, triangular shaped bone near the base of the spine



## The Skeletal System

- \_\_\_\_\_ bones fused to form one bone

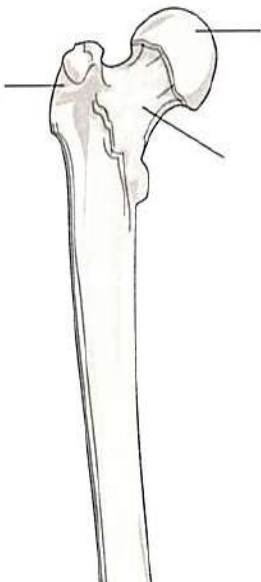
### Coccyx ( \_\_\_\_\_ ) -

- forms the end of the spine
- \_\_\_\_\_ fused bones

### Pelvic Girdle -

aka the hips of pelvic bone, protects internal organs, supports the lower extremities, made up of 3 bones fused together

- \_\_\_\_\_ - upper, blade-shaped part of the hip; one on each side
- \_\_\_\_\_ - slightly movable articulation between the sacrum and the ilium
- \_\_\_\_\_ - lower and posterior portion of the pelvic girdle
- \_\_\_\_\_ - anterior portion of the pelvic girdle
- \_\_\_\_\_ - cartilaginous joint that hold the bones firmly together
- \_\_\_\_\_ - the large socket in the pelvic bones, forms the hip socket for the head of the femur



### Legs and Knees –

#### Femur –

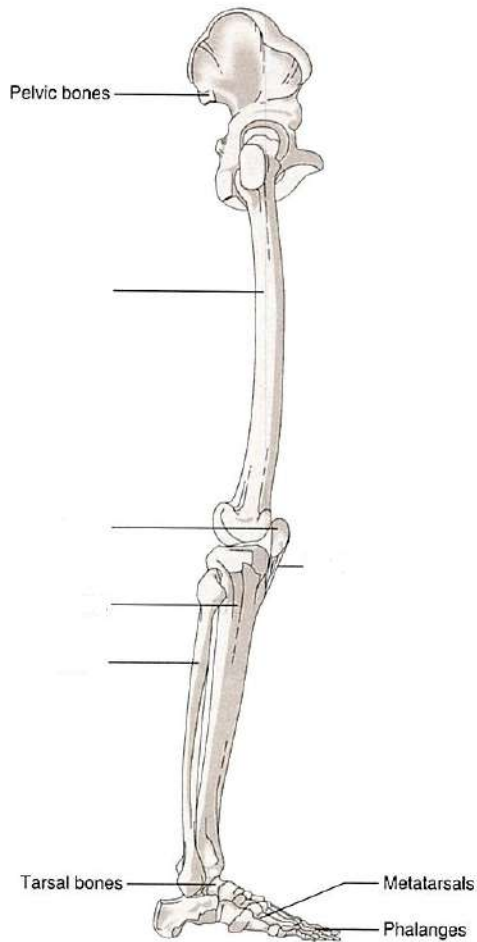
- head of the femur –
- femoral neck –
- Trochanter - is one of the two large bony projections on the upper end of the femur just below the femoral neck

#### Knees –



## The Skeletal System

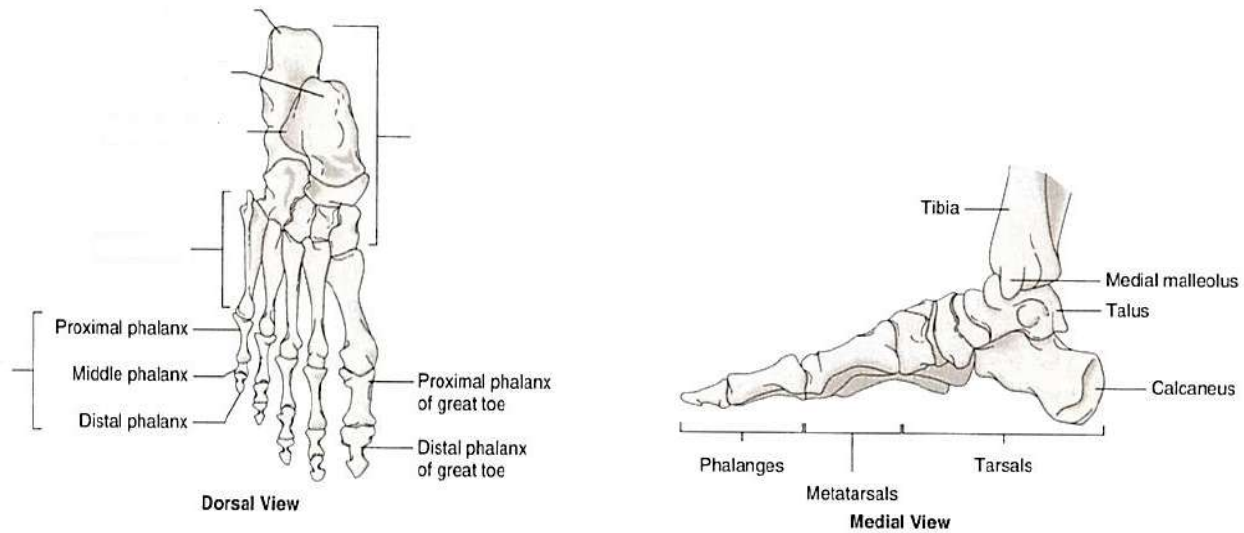
- Patella –
- Popliteal - posterior surface of the knee and is used to describe the space, ligaments, vessels, and muscles in this area
- Anterior Cruciate Ligament (\_\_\_\_\_) / Posterior Cruciate Ligament (\_\_\_\_\_) - make possible the movements of the knee



### Lower Leg –

- Tibia (shin bone) –
- Fibula -

## The Skeletal System



### Ankles and Feet –

- Tarsals - bones that make up the \_\_\_\_\_
- Malleolus - round bony protuberance on each side of the ankle
- Talus- is the ankle bone that articulates with the tibia and fibula
- Calcaneus -
- Metatarsals - are the bones of the foot.
- Phalanges - the bones of the \_\_\_\_\_

### Pathologies of the Skeletal System:

## The Skeletal System

### Joints –

- Ankylosis - loss or absence of mobility due to disease, injury or surgical procedure
- Arthralgia - joint pain
- Arthrosclerosis - stiffness of the joints
- \_\_\_\_\_ - inflammation of a bursa (repetitive stress)
- Chondroma - slow growing benign tumor derived from cartilage cells
- Chondromalacia - abnormal softening of cartilage
- Hallux Valgus - (bunion) abnormal enlargement of the at the base of the great toe
- Luxation - (\_\_\_\_\_) dislocation or displacement of a bone from its joint.
  - Subluxation –
- Synovitis - inflammation of the synovial membrane

### Arthritis –

- inflammatory condition of one or more joints
- \_\_\_\_\_ - (wear and tear arthritis) - Degenerative Joint Disease (DJD)
- Gouty arthritis - (gout) type of arthritis associated with the formation of uric acid crystals in the joint as the results of hyperuricemia
- \_\_\_\_\_ - (RA) autoimmune disorder; symptoms are generalized and usually more severe; synovial membranes are thickened; other tissues are also attacked causing the joints to become swollen, painful and immobile
- Ankylosing spondylitis - rheumatoid arthritis characterized by progressive stiffening of the spine caused by fusion of the vertebral bodies
- Juvenile rheumatoid arthritis - affects \_\_\_\_\_

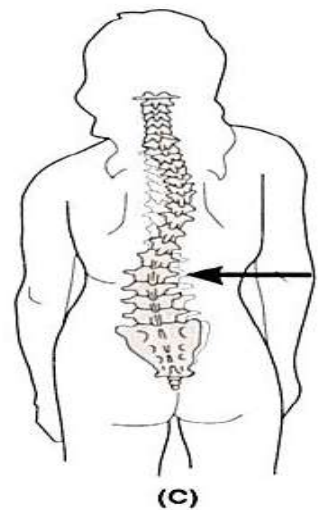
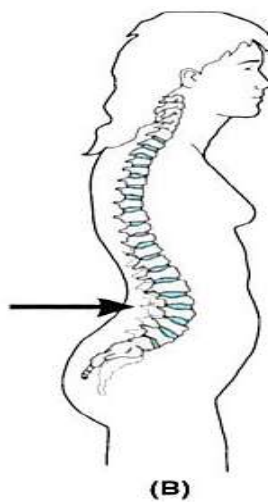
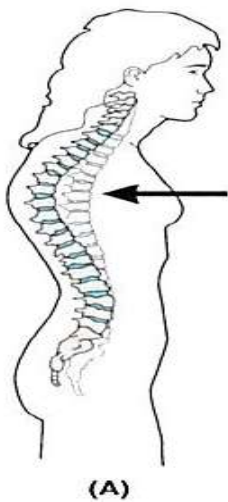
### Spinal Column -

## The Skeletal System

- \_\_\_\_\_ - (ruptured disk) a rupture to the intervertebral disk that results in pressure on the spinal nerve roots
- Lumbago - (low back pain)
- Spondylitis - inflammation of the vertebrae
- Spondylolisthesis - forward movement of the body of one of the lower lumbar vertebra on the vertebra below it or on the sacrum
- Spondylosis - degenerative condition of the vertebrae
- Spina bifida - congenital defect; where the spinal canal fails to close around the spinal cord

### Curvatures of the Spine –

- Kyphosis - \_\_\_\_\_  
(humpback/dowager's hump)
- Lordosis - \_\_\_\_\_  
(swayback)
- Scoliosis - \_\_\_\_\_



### Bones -

- Exostosis - benign growth on the surface of a bone

## The Skeletal System

- Ostealgia - any pain linked to an abnormal condition within a bone
- Osteitis - inflammation of a bone
- \_\_\_\_\_ - abnormal softening of a bone due to disease
- Osteomyelitis - inflammation of the bone and bone marrow
- Osteonecrosis - destruction and death of bone tissue caused by an insufficient blood supply, infection, malignancy, or trauma
- Paget's disease - (osteitis deformans) disease of unknown cause that is characterized by extensive bone destruction followed by abnormal bone repair
- Periostitis - inflammation of the periosteum
- Rickets - caused by calcium D deficiency in early childhood results in demineralized bones and related deformities
- Talipes - (club foot) congenital deformity in which the foot may be turned outward or inward
- **Tumors of Bones**
  - Ewing's sarcoma - group of cancers that most frequently affects children or adolescents; usually occur in the diaphysis of the long bone
  - Myeloma - malignant tumor composed of cells derived from blood-forming tissue of the bone marrow
  - Osteochondroma - most common benign tumor

### **Osteoporosis –**

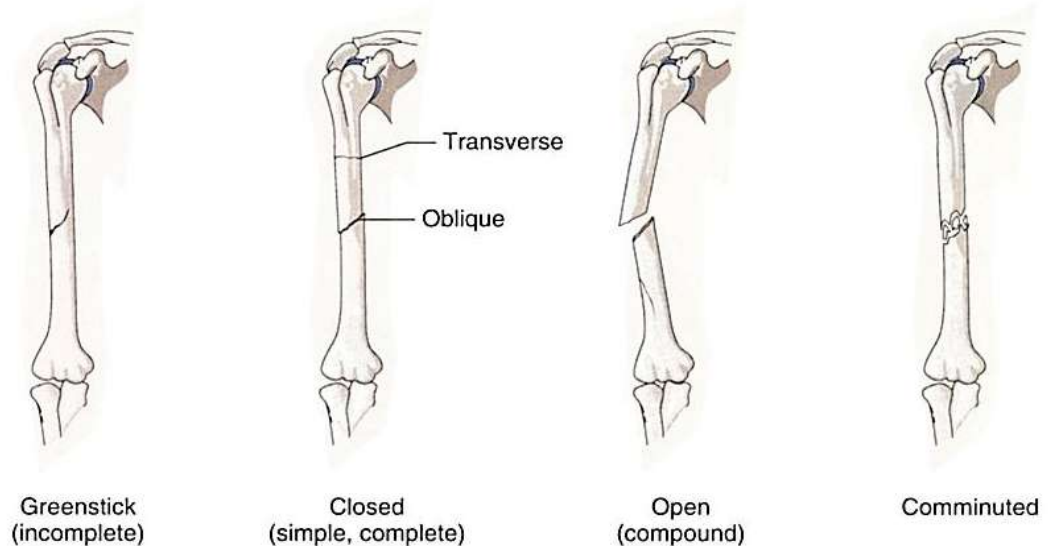
- Marked by loss of bone density and an increase in bone porosity
  - Vertebral crush fractures - (compression fractures) occur when one or more of the vertebrae become so weak that they collapse spontaneously or under minimum all stress
  - Colles' fracture - fracture of the lower end of the radius
  - Osteoporotic hip fracture - can occur spontaneously or as a result of a fall

### **Fractures –**

- (Fx) broken bone

## The Skeletal System

- Greenstick - (incomplete fracture)
- 
- Closed fracture - (simple/closed)
- 
- Open fracture - (compound)
- 
- Comminuted –
- 
- Compression –
- 
- Spiral –
- 
- Stress –



- Fat embolus - form when a long bone is fractured and fat cells from the yellow bone marrow are released into the blood
- Crepitation (crepitus) -
- \_\_\_\_\_ - formed as a bone heals; bulging deposit around the area of the break

### Diagnostic Procedures of the Skeletal System:

- Arthrocentesis - surgical puncture of the joint space to remove synovial fluid

## The Skeletal System

- Arthroscopy - visual examination of the internal structure of a joint
- Bone Density Testing (BDT) - (bone mass measurement/densitometry) use of several types of radiation tests to determine bone density
- Bone Marrow Biopsy (BMB) - performed by inserting a sharp needle into the hipbone or sternum and removing bone marrow cells.
- Bone Scan - use of nuclear medicine to detect bone cancer and osteomyelitis
- Dual X-Ray Absorptiometry (DXA) - a low-exposure radiographic measurement that is most often used to detect early signs osteoporosis
- Ultrasonic bone density testing (bone sonometer) uses sound waves to take measurements of the heel bone
- Magnetic Resonance Imaging (MRI) - used to image soft tissue structures
- Radiographs (X-Rays) - used to visualize fractured bones

### Treatment Procedures of the Skeletal System:

#### **Medications –**

- Nonsteroidal anti-inflammatory drugs (NSAIDs) - used to control pain and inflammation
- Acetaminophen - controls pain
- Antipyretics - Fever reducers
- COX-2 inhibitors - control pain and inflammation of osteoarthritis and RA

#### **Bone Marrow Transplant (BMT)** - (stem cell transplant) used to treat certain types of cancers

- Autologous Transplant - using some of the patient's own bone marrow that was harvested before treatment began
- Allogenic Transplants - using bone marrow from a donor
- Cord Blood - collected from the umbilical cord immediately after birth

#### **Joints -**

- Arthroscopic surgery - treatment of the interior of a joint
- Bursectomy - surgical removal of a bursa

## The Skeletal System

- \_\_\_\_\_ - surgical repair of cartilage
- Synovectomy - surgical removal of the synovial membrane of a joint
- Arthrodesis - (fusion/surgical ankylosis) surgical process to stiffen a joint
- Arthrolysis - surgical loosening of an ankylosed joint
- Periosteotomy - an incision through the periosteum

## Joint Replacement –

- \_\_\_\_\_ - any surgical repair of a damaged joint
- Prosthesis/implant - a substitute for a diseased or missing part of the body
- Total Knee Replacement (TKR) - all parts of the knee are replaced
- Partial Knee Replacement (PKR) - only part of the knee was replaced
- Total Hip Replacement (THR) - consists of two components; thigh and socket
- Revision surgery - replacement of a worn or failed implant

## Spinal Column –

- Discectomy - surgical removal of an intervertebral disk
- Percutaneous discectomy - a thin tube is inserted through the skin of the back to suction out the ruptured disk or to vaporize it with a laser
- Laminectomy - surgical removal of a lamina from a vertebra
- Spinal Fusion - technique to immobilize part of the spine by joining together two or more vertebra



## The Skeletal System

### Bones –

- Craniectomy - surgical removal of a portion of the skull
- Craniotomy - (bone flap) surgical incision or opening into the skull that is performed to gain access to part of the brain.
- Cranioplasty - surgical repair of the skull
- Osteoclasis - surgical fracture of a bone to correct a deformity
- Ostectomy - surgical removal of bone
- Osteoplasty - surgical repair of bones
- \_\_\_\_\_ - suturing or wiring together of bones
- Osteotomy - surgical incision or sectioning of bone; used to realign a joint damaged by arthritis

### Treatment of Fractures -

- \_\_\_\_\_ (closed reduction) - attempt to realign the bone involved or joint dislocation
- Traction - pulling force exerted on a limb in a distal direction in an effort to return the bone or joint to normal alignment
- Immobilization (stabilization) - act of holding, suturing, or fastening the bone in a fixed position with strapping or cast
- External Fixation - fracture treatment procedure in which pins are placed through the soft tissue and bone so that an external appliance can be used to hold the pieces of bone firmly in place while healing
- Internal Fixation (open reduction internal fixation (ORIF)) - fracture treatment procedure in which pins or a plate are placed directly into the bone to hold the broken pieces in place.

### Medical Specialties Related to the Skeletal System:

- |                         |                                      |
|-------------------------|--------------------------------------|
| • Chiropractor          | • Emergency Medical Technician (EMT) |
| • Orthopedic Surgeon    | • Paramedic (EMT-P)                  |
| • Orthotics             | • Prosthetist                        |
| • Osteopathic Physician | • Podiatrist                         |
| • Podiatrist            | • Podiatric Medical Assistant        |
| • Rheumatologist        | • Orthopedic Assistant               |
| • Rheumatism            |                                      |