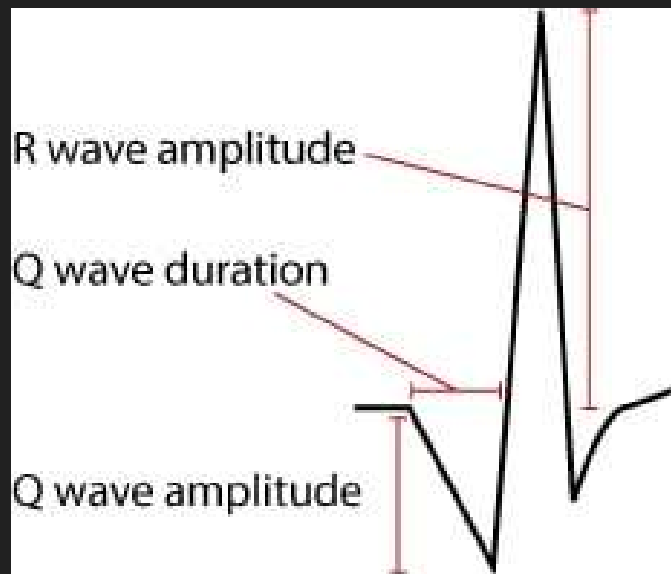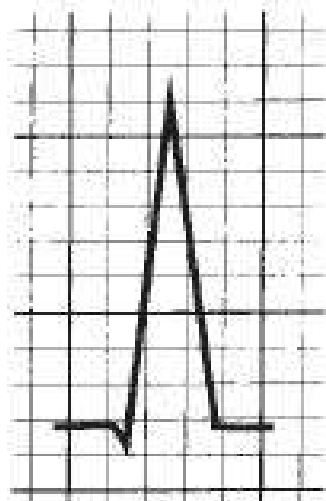


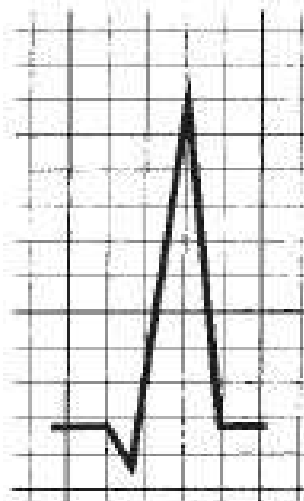
Definition of pathological Q wave

- Duration >0.03 seconds and/or
- Amplitude $>25\%$ of R wave amplitude

Hence, the Q wave visible here does fulfill criteria for pathological Q waves.



Normal
Q wave



Pathologic
Q wave

Figure 4.21. Compared with small Q waves generated during normal depolarization, pathologic Q waves are more prominent with a width ≥ 1 mm (1 small box) and depth $>25\%$ of the height of the QRS complex.