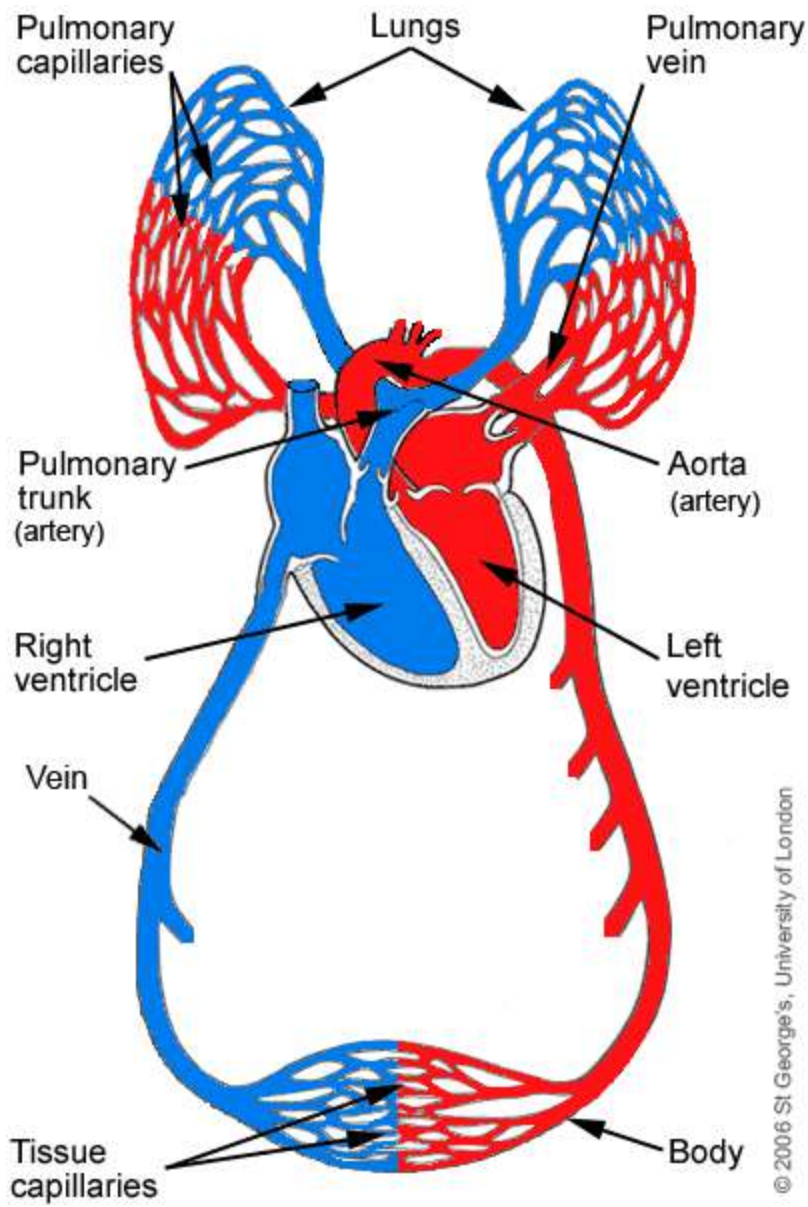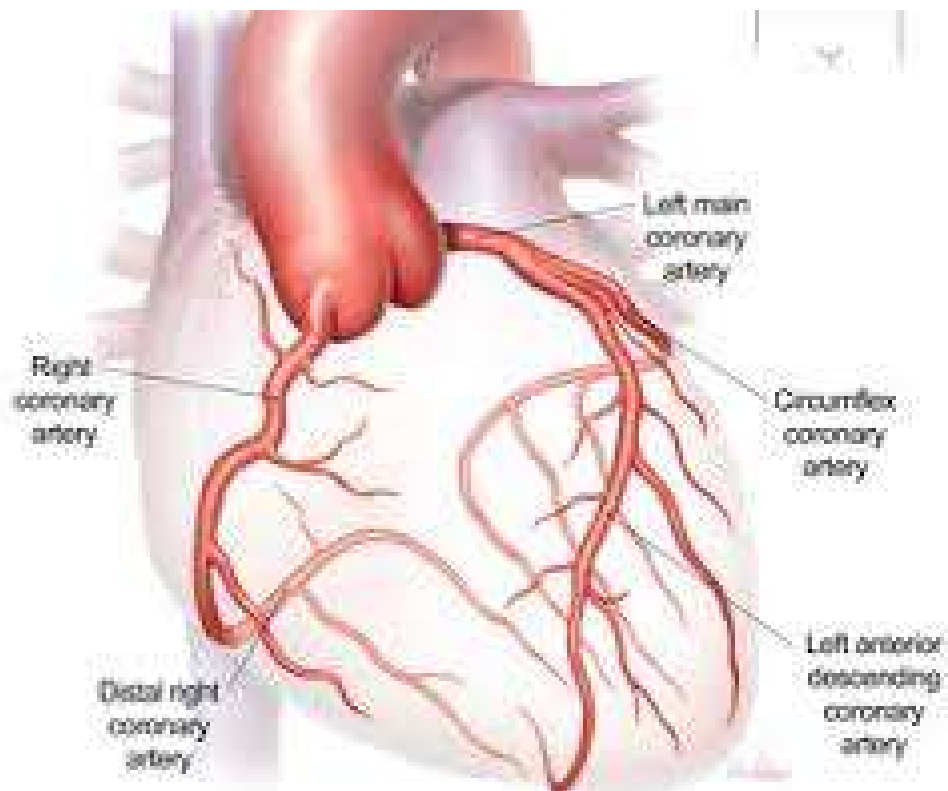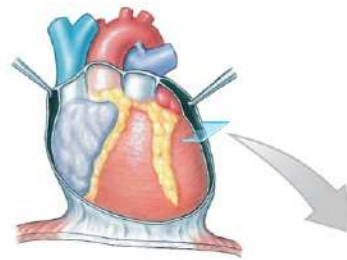


A section of the heart showing its three layers: epicardium, myocardium, and endocardium



Myocardium

Muscular wall of the heart consisting primarily of cardiac muscle cells

Endocardium

Covers the inner surfaces of the heart

Endothelium
Areolar tissue

Pericardial cavity
(contains serous fluid)

Parietal Pericardium

The serous membrane that forms the outer wall of the pericardial cavity; it and a dense fibrous layer form the pericardial sac surrounding the heart

Dense fibrous layer
Areolar tissue
Mesothelium

Epicardium

Covers the outer surface of the heart; also called the visceral pericardium

Mesothelium
Areolar tissue

Connective tissues