
BODY PLANES, DIRECTIONS, AND CAVITIES

Course

*Principles of
Health Science*

Unit III

*Anatomy and
Physiology*

**Essential
Question**

*What common
terminology is
used to describe
human
anatomy?*

TEKS

*130.202 (c) 1D,
1E, 1G, 2D*

**Prior Student
Learning**

n/a

Estimated time

1-2 hours

Rationale

To pursue a career in health care, proficiency in anatomy and physiology is vital.

Objectives

Upon completion of this lesson, the student will be able to:

- Locate body cavities and list contents
- Identify body directions
- Recognize body directions
- Identify body cavities and body planes

Engage

Discuss the following question with the class:

Why is it important for healthcare workers to know anatomical terms?

Key Points

- I. Body cavities - openings within the torso which contain organs, protect delicate organs from accidental shocks and bumps, and permit the expansion and contraction of organs without disrupting the activities of other organs.
 - A. Dorsal cavity - located on the posterior/dorsal surface of the body and surrounds the brain and the spinal cord.
 1. Cranial Cavity - The bones of the skull create the cranial cavity to protect the brain.
 2. Spinal (Vertebral) Cavity - formed by the vertebrae of the spine and surrounds the spinal cord.
 - B. Ventral Cavity - located on the anterior/ventral surface of the body which contains the chest and abdomen. The walls are composed of skin, muscle, connective tissue, bone (for two cavities), and the serous membrane.
 1. Thoracic Cavity - the portion of ventral cavity superior to the diaphragm.
 - a. Pleural Cavities - the spaces surrounding each lung.
 - b. Mediastinum - a broad middle tissue mass of the thoracic cavity dividing the lungs into two cavities. It includes the aorta, other great blood vessels, esophagus, trachea, thymus, pericardial cavity, and heart.
 - c. Pericardial Cavity - space in which the heart is located.
 2. Abdominopelvic Cavity - the portion of the ventral

cavity inferior to the diaphragm.

- a. Abdominal Cavity - The superior portion of the abdominopelvic cavity. It extends from the diaphragm to the superior margin of the pelvic girdle. The abdominal cavity contains the organs known as the viscera which include the stomach, spleen, liver, gallbladder, pancreas, small intestine, and most of the large intestine.
 - b. Pelvic Cavity - the pelvic cavity is surrounded by the pelvic bones. The pelvic cavity contains the urinary bladder, cecum, appendix, sigmoid colon, rectum, and the male or female internal reproductive organs.
- II. Abdominal Regions – the abdominal/pelvic cavity is so large that it is divided into regions
- A. One method of division is quadrants. Quadrants divide the abdominal/pelvic cavity into four sections using the belly button as the point of reference for both the horizontal and vertical lines.
 - 1. Right upper quadrant (RUQ)
 - 2. Left upper quadrant (LUQ)
 - 3. Right lower quadrant (RLQ)
 - 4. Left lower quadrant (LLQ)
 - B. A more precise method of division is abdominal regions. This method divides the area into a tic tac toe board
 - 1. Epigastric – above the stomach
 - 2. Umbilical – near the umbilicus or belly button
 - 3. Hypogastric / pelvic – below the stomach
 - 4. Hypochondriac – below the ribs
 - 5. Lumbar/Lateral – near the large bones of the spinal cord
 - 6. Iliac / inguinal – near the groin
- III. Body planes - refer to any slice or cut through a three-dimensional structure allowing us to visualize relationships between those parts. CT and MRI technology use these principles.
- A. Sagittal: divides the body or organ vertically into right and left unequal parts: words used with the sagittal plane include-medial, lateral, proximal and distal.
 - B. Midsagittal: divides the body or organ vertically into equal right and left parts
 - C. Frontal/ Coronal: a vertical plane dividing the body or an organ into anterior (front) and posterior (back) sections.
 - D. Transverse: a horizontal plane dividing the body or an organ into superior (upper) and inferior (lower) sections.

IV. Body Directions

- A. Superior – upper, or above something
- B. Inferior – lower, or below something
- C. Anterior or Ventral – front, in front of
- D. Posterior – After, behind, following, toward the rear
- E. Medial – Toward the mid-line, middle, away from the side
- F. Lateral – toward the side of the body - away from the mid-line
- G. Proximal – toward or near the trunk of the body, near the point of attachment to the body
- H. Distal – Away from, farther from the origin or attachment to the body
- I. Dorsal: Near the upper surface, toward the back
- J. Ventral: Toward the bottom, toward the belly
- K. Rostral: Toward the front
- L. Cranial - refers to the head of the body
- M. Caudal – means tail end
- N. Internal – inside the body

Activity

- I. In pairs, create a stick-like figure, with a head, trunk, arms, and legs using clay. As the terms are discussed, the student will use a toothpick to designate the area. After all the terms are discussed, cut the figure into the planes.
- II. In pairs, identify the following areas on partner:
 - Area distal to the knee.
 - Area proximal to the elbow.
 - Lateral to the big toe.
 - Anterior side of the body.
 - Posterior side of the body.
 - Area that is medial to the shoulder.
 - Area that is superior to the lungs.
 - Area that is inferior to the heart.
- III. Complete **Color the Cavities and Color the Abdominal Regions** activity.
- IV. Complete the **Body Planes and Directions** activity.
- V. Develop a Short Story describing best date or worst nightmare using **anatomical terms**.
- VI. Show students copies of CT-scans and quiz them on which body plane is being used.

Assessment

Writing Rubric

Body Orientation Quiz and Key

Materials

Assorted colors of clay

Crayons

Colored toothpicks

Paper plates

Rulers

Bananas

Permanent markers

<http://www.ama-assn.org/ama/pub/physician-resources/patient-education-materials/atlas-of-human-body.shtml> - atlas of the human body

Utah State Office of Education, (2005). *Medical Anatomy and Physiology Teacher Resource CD*. Utah.

Accommodations for Learning Differences

For reinforcement, the students will make flashcards of all of the terms.

For enrichment, the students will develop questions and design a jeopardy game utilizing the information in this unit.

National and State Education Standards

National Health Science Cluster Standards

HLC01.01 Academic Foundations

Health care workers will know the academic subject matter required (in addition to state high school graduation requirements) for proficiency within their area. They will use this knowledge as needed in their role.

HLC10.01 Technical Skills

Health Care Workers will apply technical skills required for all career specialties. They will demonstrate skills and knowledge as appropriate.

TEKS

130.202 (c)(1)(D) organize, compile, and write ideas into reports and summaries;

130.202 (c) (1)(E) plan and prepare effective oral presentations; and

130.202 (c) (1)(G) describe biological and chemical processes that maintain homeostasis.

130.202 (c)(2)(D) accurately interpret, transcribe, and communicate medical vocabulary using appropriate technology.

Texas College and Career Readiness Standards

English Language Arts

II. B. Understand new vocabulary and concepts and use them accurately in reading writing and speaking.

III. B. Develop effective speaking styles for both groups and one on one

situations.

IV. A. Apply listening skills as an individual and as a member of a group in a variety of settings.

IV. B. 2. Listen actively and effectively in one-on-one communication situations.

Science

1.E.1. Use several modes of expression to describe or characterize natural patterns and phenomena. These modes of expression include narrative, numerical, graphical, pictorial, symbolic, and kinesthetic.

1.E.2. Use essential vocabulary of the discipline being studied.

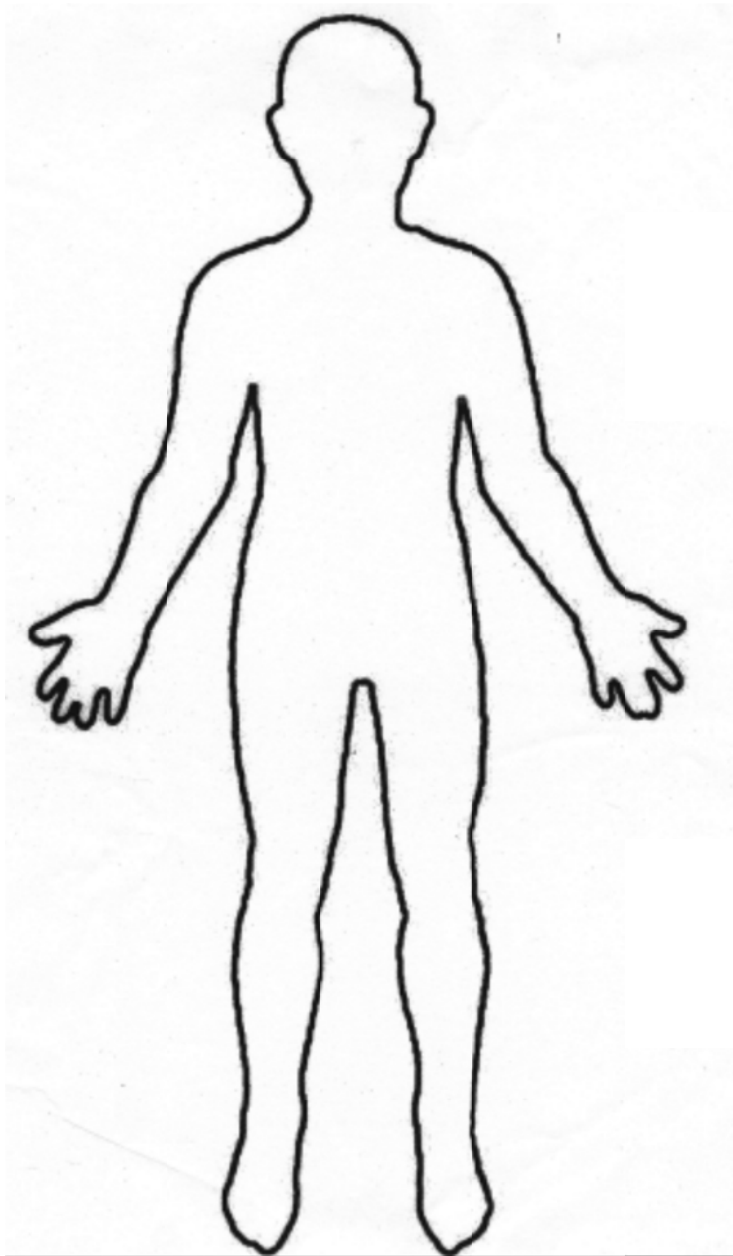
3.A.1. Use correct applications of writing practices in scientific communication.

Color the Cavities

Using a diagram of the human body, label and color code each of the following.

Ventral Cavity
Thoracic Cavity
Pleural Cavities
Pelvic Cavity

Mediastinum
Pericardial Cavity
Abdominopelvic Cavity
Abdominal Cavity

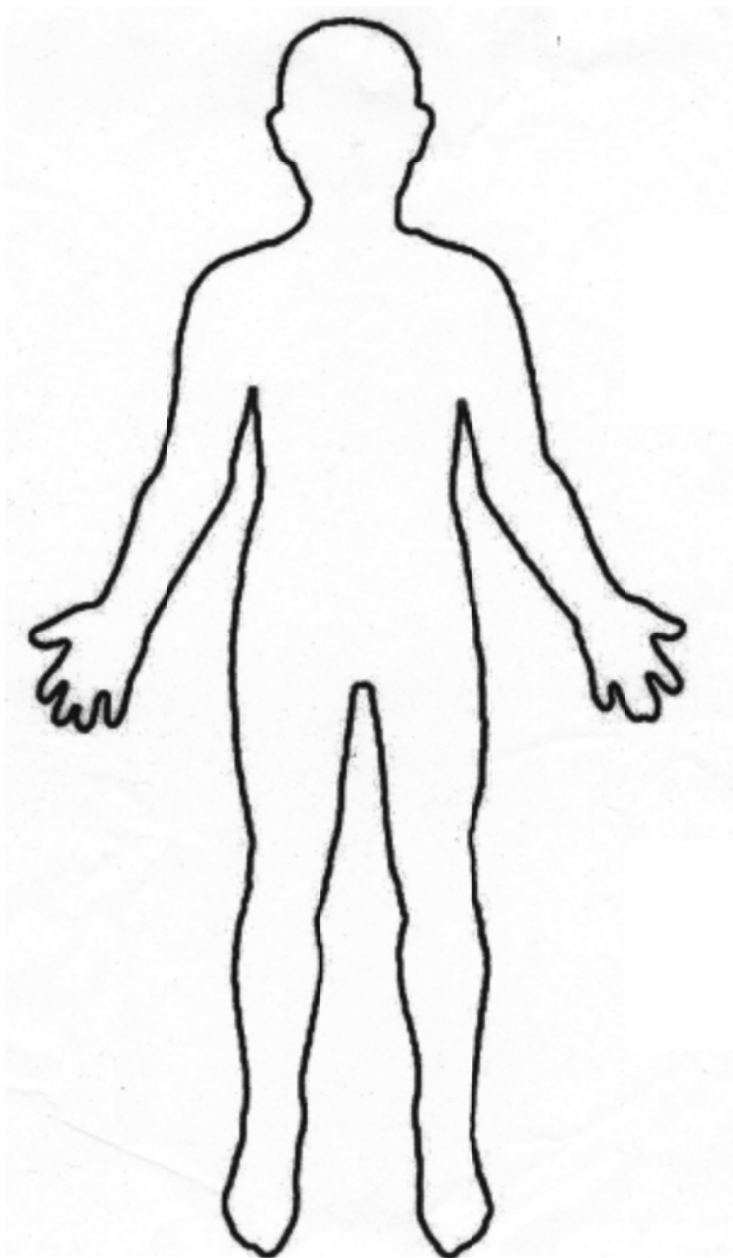


Color the Cavities

Using a diagram of the human body, label and color code each of the following.

Dorsal cavity
Spinal (Vertebral) Cavity

Cranial Cavity

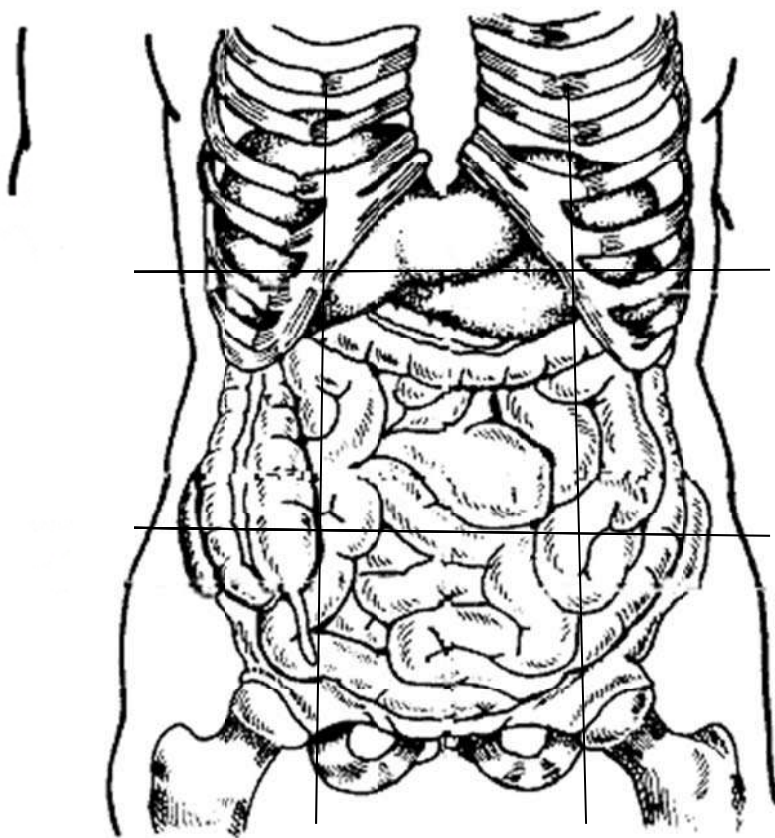


Color the Abdominal Regions

A. Color the following drawing using the body regions:

1. Right iliac- purple
2. Epigastric- red
3. Left lumbar- blue
4. Right hypochondriac- yellow
5. Umbilical- orange
6. Left iliac- pink
7. Right lumbar-green
8. Hypogastric- brown
9. Left hypochondriac- leave blank

B. Using a black marker label the 4 abdominal quadrants.



Body Planes and Directions Activity

Planes and directions are practiced using fruit and toothpicks.

Be careful with the surgical instruments. Read and follow the instructions very carefully.

Materials:

Knives
Marker
Colored toothpicks
Bananas
Rulers

Banana:

Cut the banana with a transverse plane. Stick a blue toothpick in the superior end of the banana. Place red toothpick in the most distal point on the right inferior piece. Make a 3cm midsagittal incision on the posterior inferior portion of your banana. Place a yellow toothpick at the anterior superior medial section of the banana. With a marker place a (X) on the left posterior superior lateral section on your banana.

Short Story

Incorporate the following terms into a story describing your describing your worst nightmare. Underline the term(s) in the story.

Superior
Inferior
Anterior
Abdominal Cavity
Dorsal
Pelvic Cavity
Medial
Oral Cavity
Lateral
Proximal
Distal
Superficial
Deep
Skeletal System
Cardiovascular System

Body Orientation Quiz

1. Describe how a body would be divided by each of the following types of planes:

- A. Frontal (Coronal)
- B. Midsagittal
- C. Sagittal
- D. Transverse

2. Identify the correct directional term to complete the following statements.

- A. The liver is _____ to the diaphragm.
- B. Fingers are located _____ to the wrist bones.
- C. The skin on the dorsal surface of your body is said to be located on your _____ surface.
- D. The great (big) toe is _____ to the little toe.
- E. The skin on your leg is _____ to the muscle tissue in your leg.
- F. When you float face down in a pool, you are lying on your _____ surface.
- G. The lungs and the heart are located _____ to the abdominal organs.

3. Identify which cavity each of the following organs are in:

- | | |
|----------------------|--------------------------|
| A. Heart _____ | G. Lungs _____ |
| B. Liver _____ | H. Spleen _____ |
| C. Intestines _____ | I. Kidneys _____ |
| D. Spinal Cord _____ | J. Stomach _____ |
| E. Brain _____ | K. Urinary Bladder _____ |
| F. Sex Organs _____ | L. Pancreas _____ |

4. Fill in the blank completing the analogy.

- A. anterior is to ventral as posterior is to _____
- B. superficial is to external as deep is to _____
- C. cranial is to caudal as superior is to _____
- D. medial is to lateral as proximal is to _____

5. Match the organs with the cavity they are in.

CAVITY

1. ____ cranial cavity
2. ____ spinal cavity
3. ____ thoracic cavity
4. ____ abdominal cavity
5. ____ pelvic cavity

ORGAN

- A. stomach
- B. reproductive organs
- C. brain
- D. small intestines
- E. urinary bladder
- F. spinal cord
- G. liver, gallbladder, pancreas and spleen
- H. lung

6. Match the abdominal region with the descriptive term:

1. ____ Iliac/inguinal
2. ____ Epigastric
3. ____ Lumbar/lateral
4. ____ hypochondriac
5. ____ Umbilical
6. ____ hypogastric/ pelvic

- A. above the stomach
- B. near the belly button
- C. below the stomach
- D. below the ribs
- E. near the large bones of spinal cord
- F. near the groin

("Medical anatomy and," 2005)

Quiz Key

1. Describe how a body would be divided by each of the following types of planes:

- A. Frontal (coronal) - **divides body into anterior and posterior sections.**
- B. Midsagittal - **divides body into equal right and left sides.**
- C. Sagittal - **divides body into right and left sides.**
- D. Transverse - **divides body into superior and inferior sections.**

2. Identify the correct directional term to complete the following statements.

- A. The liver is **inferior** to the diaphragm
- B. Fingers are located **distal** to the wrist bones.
- C. The skin on the dorsal surface of your body is said to be located on your **posterior** surface.
- D. The great(big) toe is **medial** to the little toe.
- E. The skin on your leg is **superficial** to the muscle tissue in your leg.
- F. When you float face down in a pool, you are lying on your **anterior** surface.
- G. The lungs and the heart are located **superior** to the abdominal organs.

3. Identify which cavity each of the following organs are in:

- | | |
|-------------------------------------|----------------------------------|
| A. Heart ventral/mediastinal | G. Lungs ventral/pleural |
| B. Liver abdominal | H. Spleen abdominal |
| C. Intestines abdominal | I. Kidneys abdominal |
| D. Spinal Cord vertebral | J. Stomach abdominal |
| E. Brain cranial | K. Urinary Bladder pelvic |
| F. Sex Organs pelvic | L. Pancreas- abdominal |

4. Fill in the blank completing the analogy.

- A. anterior is to ventral as posterior is to **dorsal**
- B. superficial is to external as deep is to **internal**
- C. cranial is to caudal as superior is to **inferior**
- D. medial is to lateral as proximal is to **distal**

5. Match the organs with the cavity they are in.

CAVITY

- 1. **C** cranial cavity
- 2. **F** spinal cavity
- 3. **H** thoracic cavity
- 4. **A, D, G** abdominal cavity
- 5. **B, E** pelvic cavity

ORGAN

- A. stomach
- B. reproductive organs
- C. brain
- D. small intestines
- E. urinary bladder
- F. spinal cord
- G. liver, gallbladder, pancreas and spleen
- H. lung

6. Match the abdominal region with the descriptive term:

- | | |
|--------------------------------------------|----------------------------------------|
| 1. <u> F </u> Iliac/inguinal | A. above the stomach |
| 2. <u> A </u> Epigastric | B. near the belly button |
| 3. <u> E </u> Lumbar/lateral | C. below the stomach |
| 4. <u> D </u> hypochondriac | D. below the ribs |
| 5. <u> B </u> Umbilical | E. near the large bones of spinal cord |
| 6. <u> C </u> hypogastric/ pelvic | F. near the groin |

("Medical Anatomy and," 2005)