


Wrist and Hand injuries




Anatomy

-
-
-
-

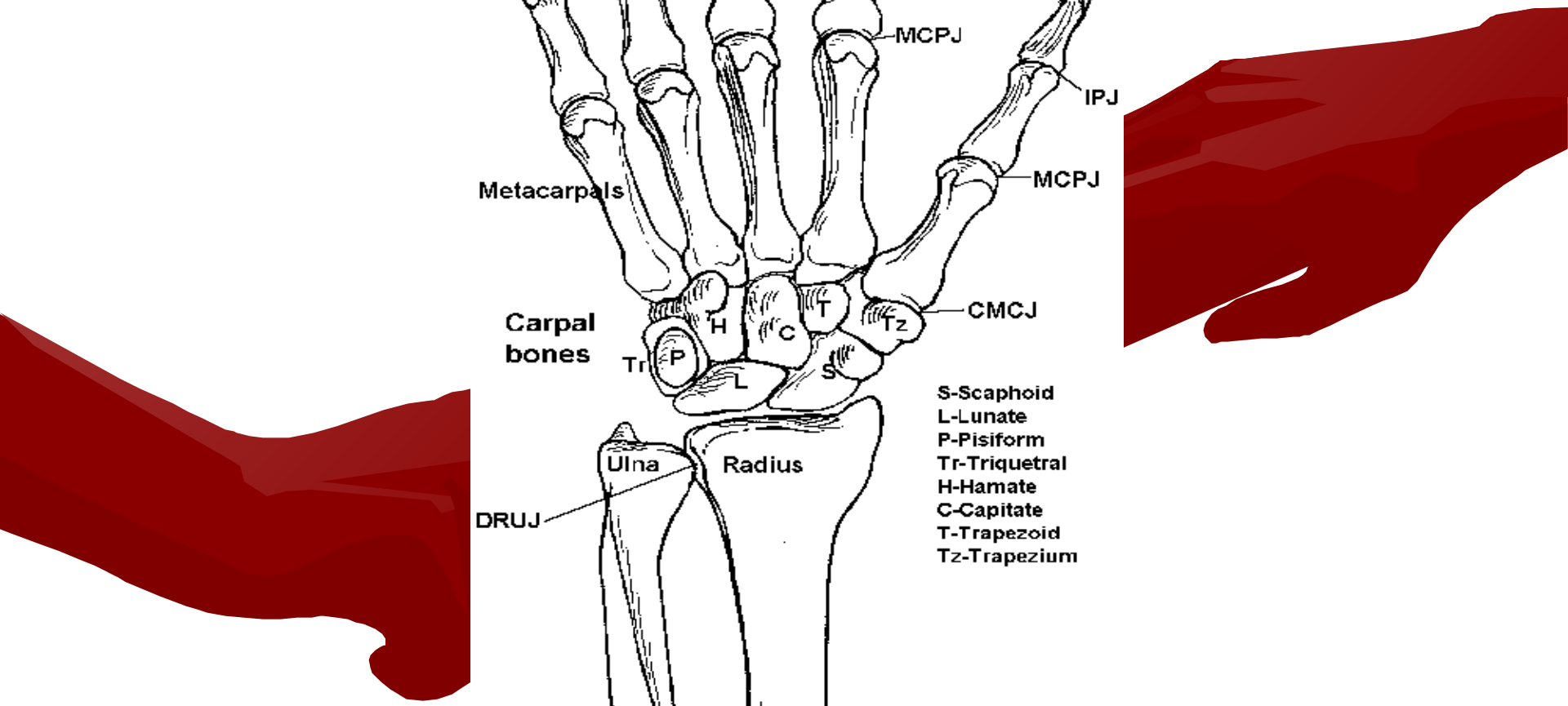
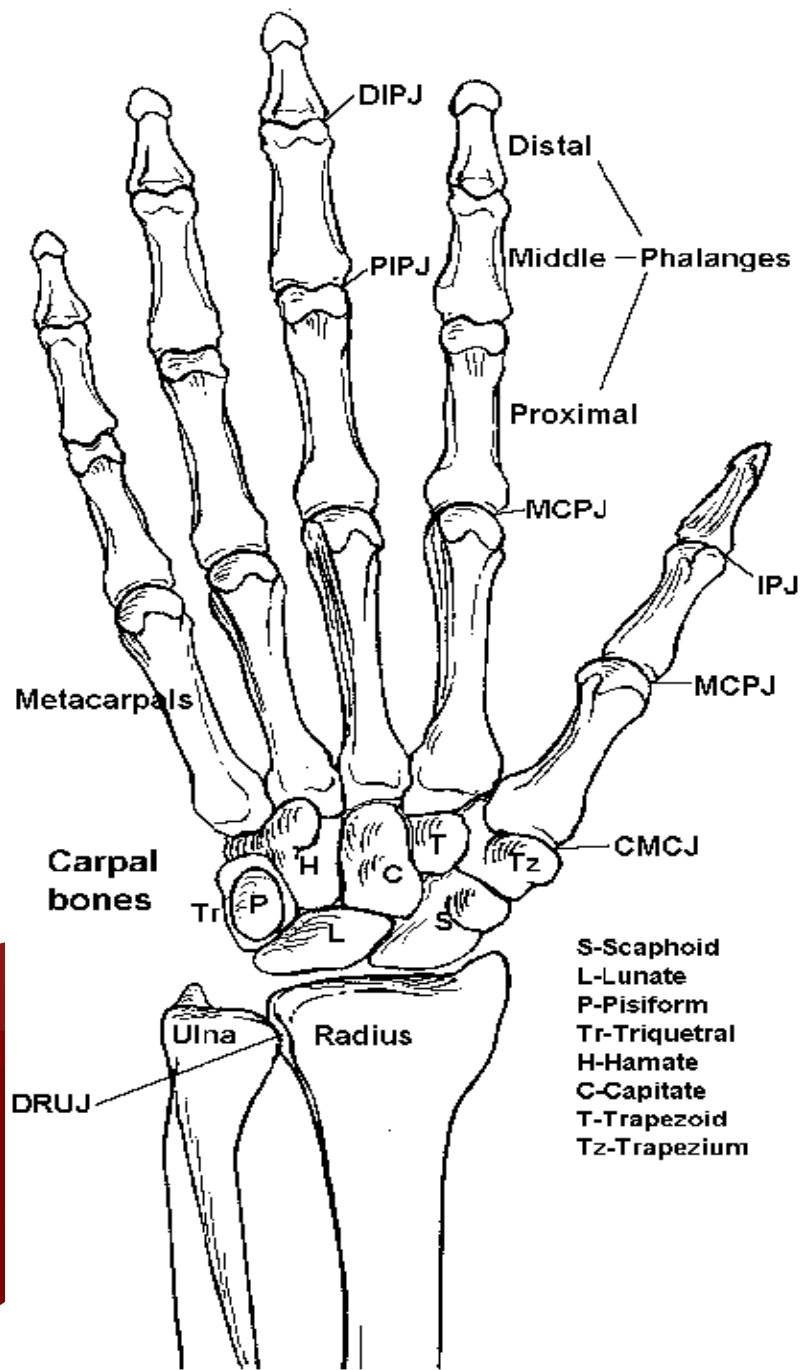


Bones




Carpals






Metacarpals

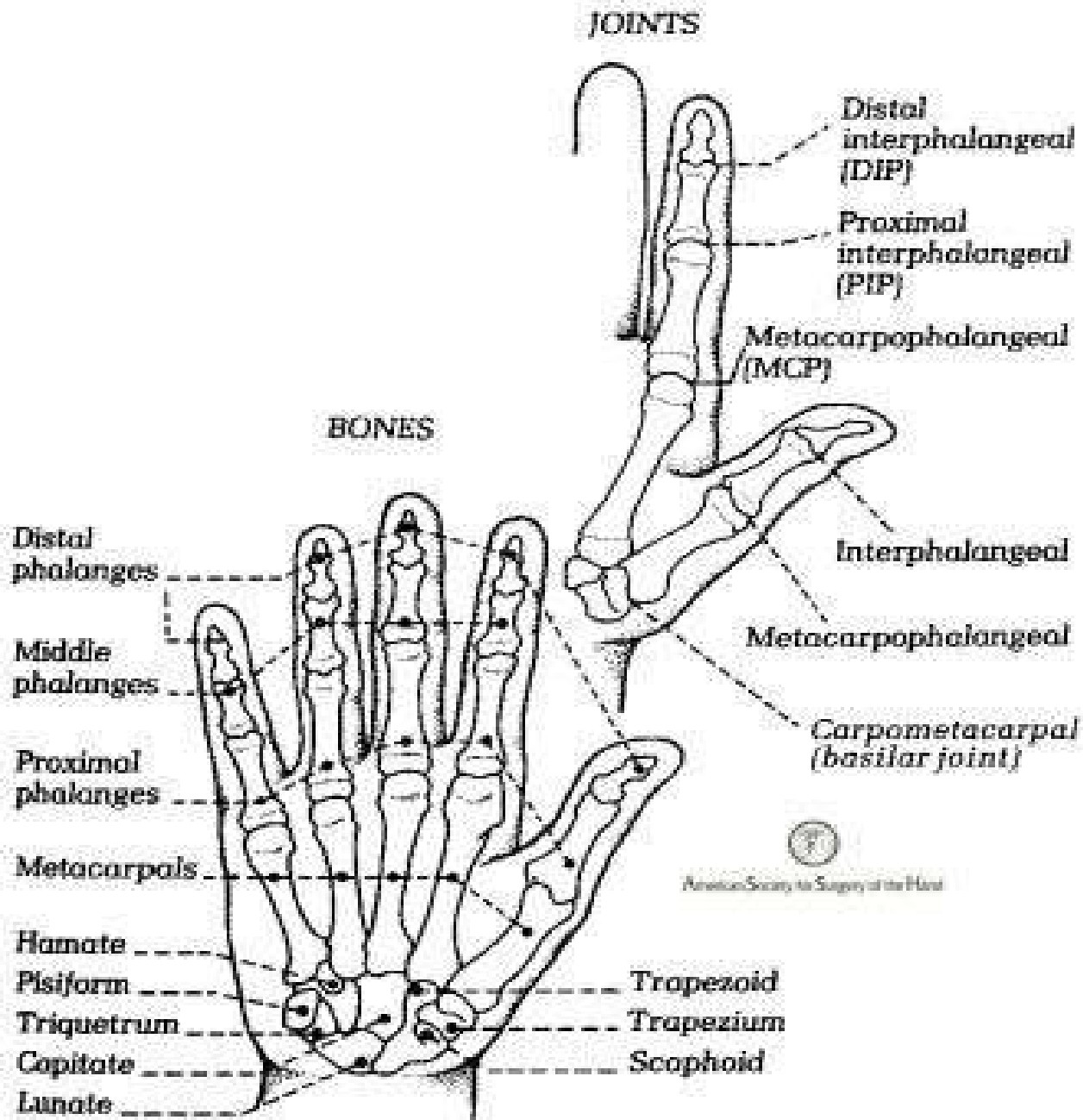
-
-
-
-




Phalanges

-
-
-



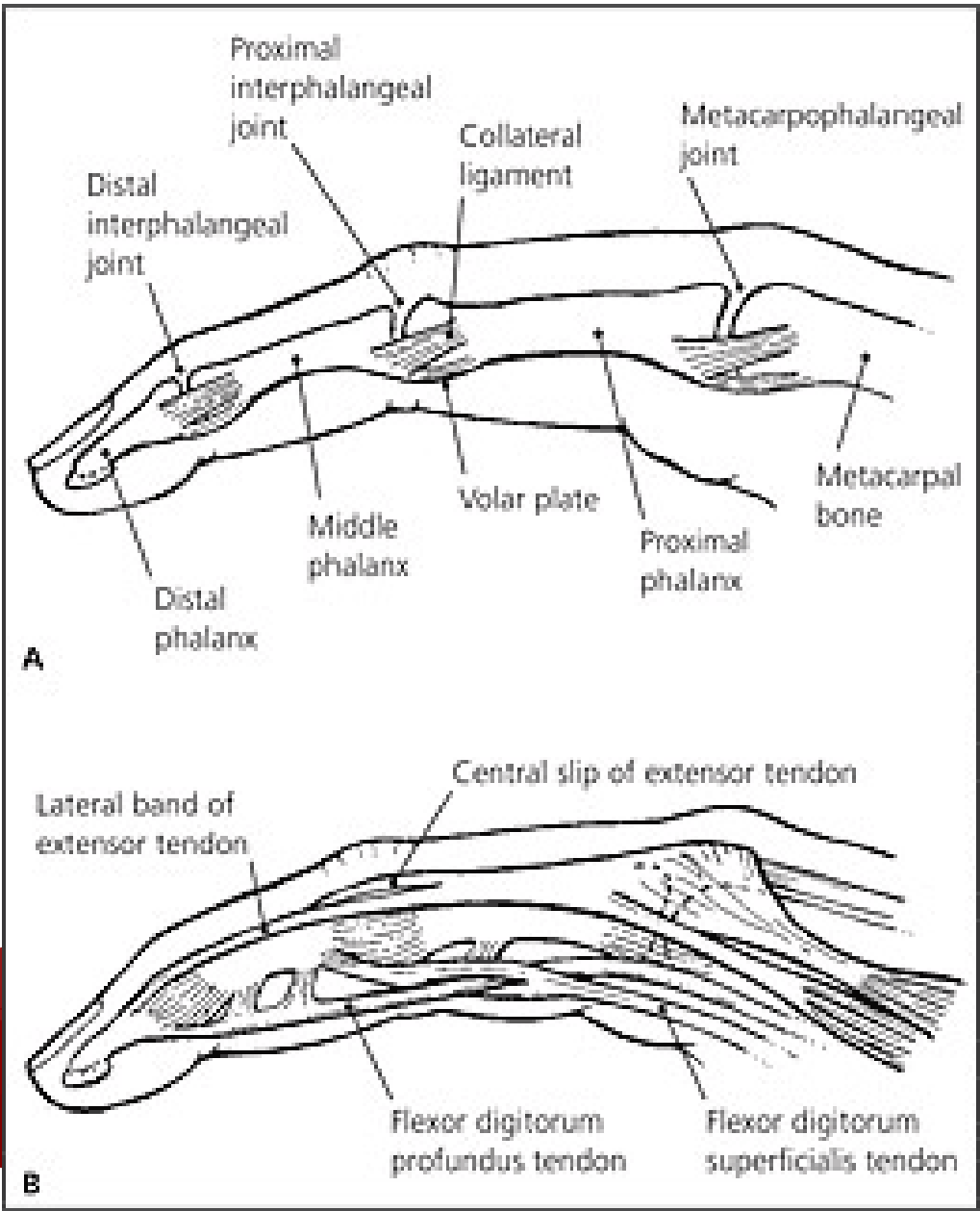


Joints




Ligaments

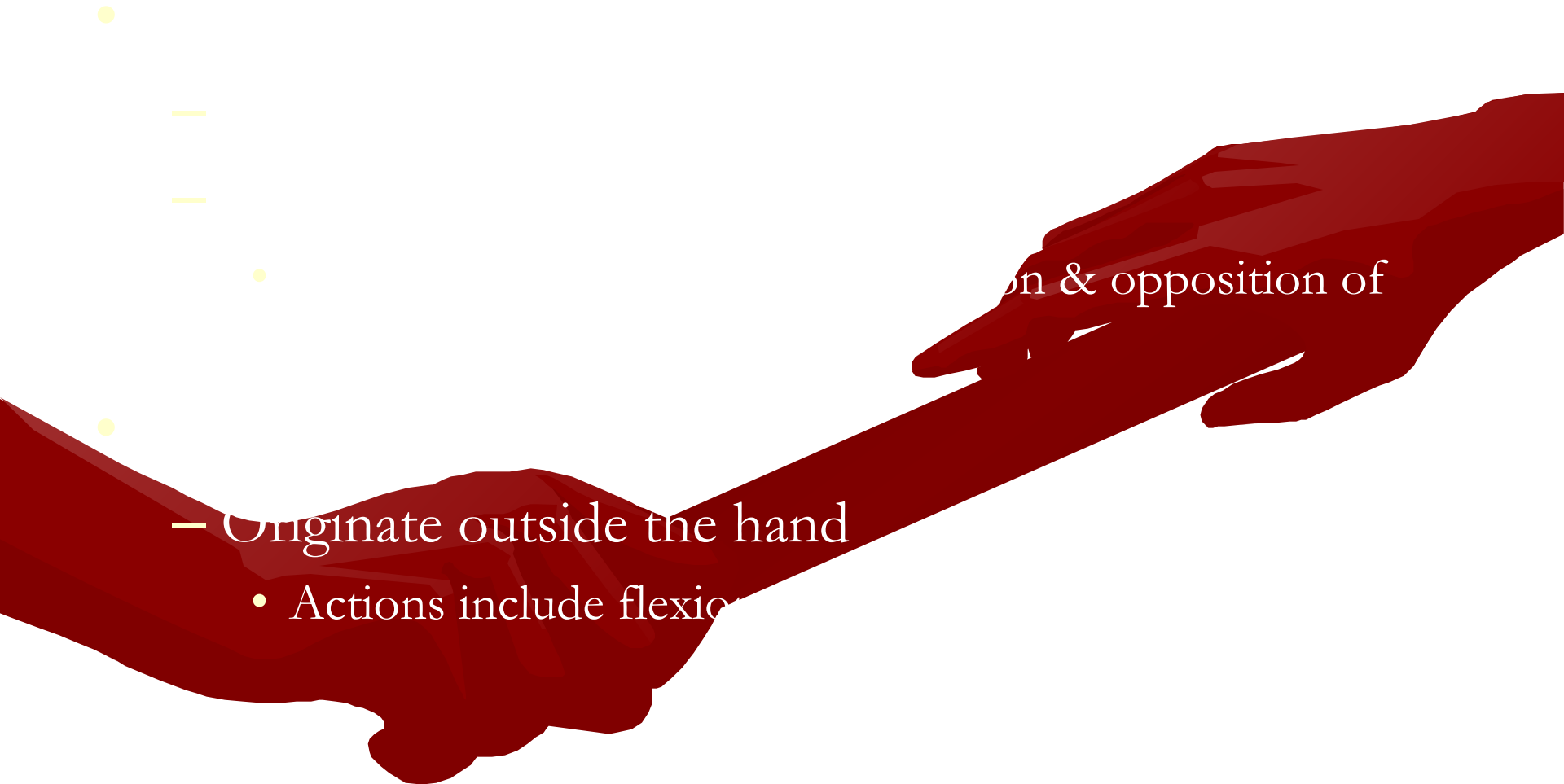
- Volar plate (thickened articular capsule)
- Ulnar collateral ligament (UCL)
- Radial collateral ligament (RCL)
- Ulnar collateral ligament (UCL) - resurfaces volar aspect
- Radial collateral ligament (RCL) - collateral (at IP)
- Joint capsule
- Volar plate (thickened articular capsule)



© 2006 MARY ALBURY-NOYLES



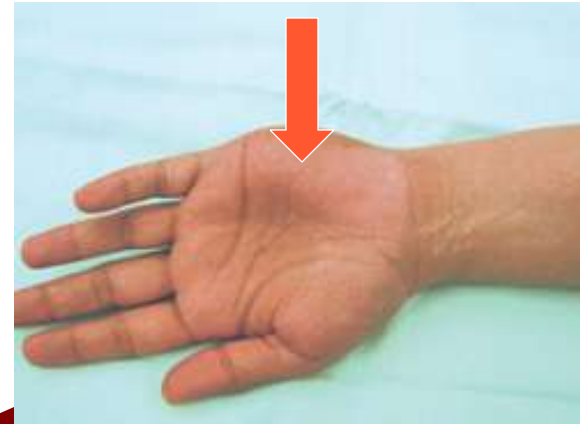
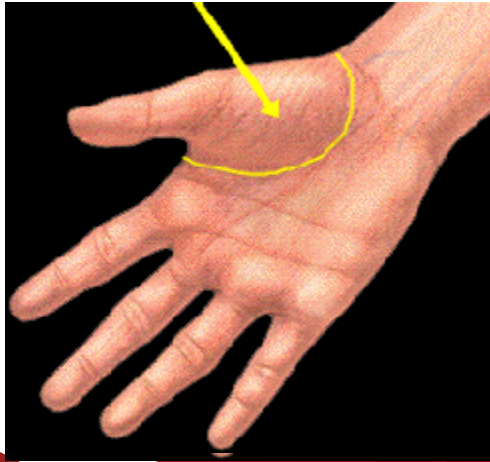
Muscles

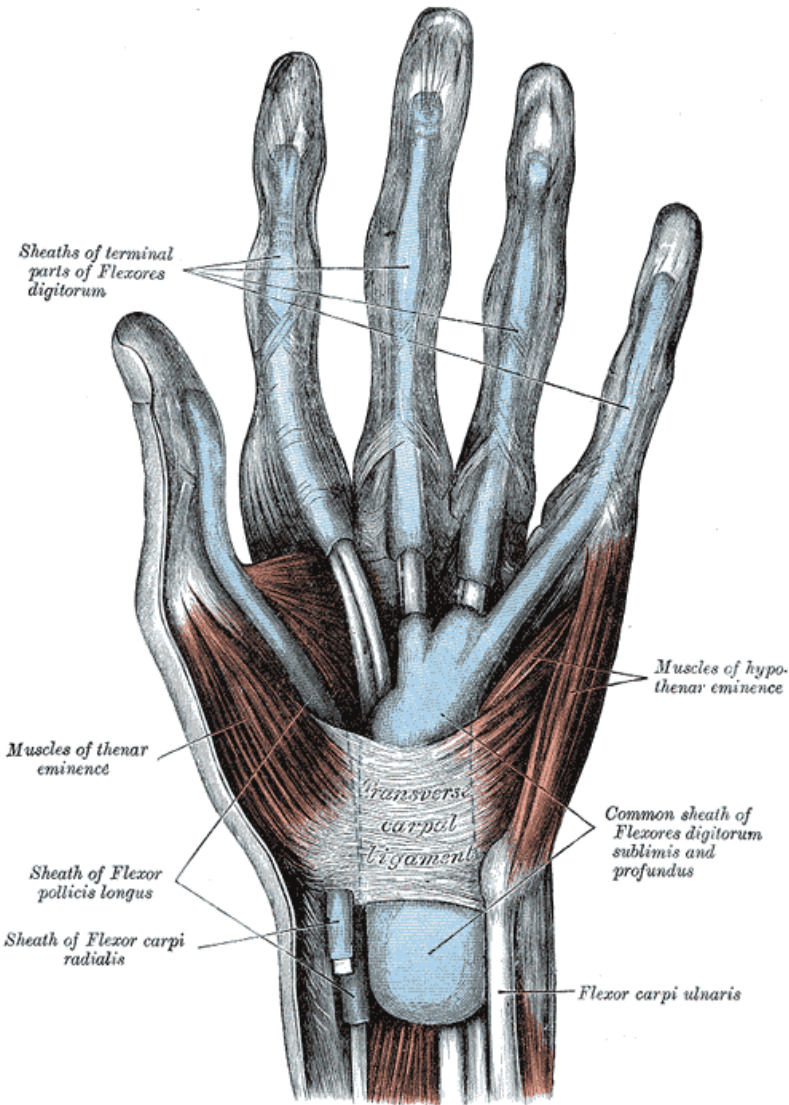


- Originate outside the hand
 - Actions include flexion

on & opposition of

Thenar & hypothenar eminence





Sheaths of terminal parts of Flexores digitorum

Muscles of thenar eminence

Sheath of Flexor pollicis longus

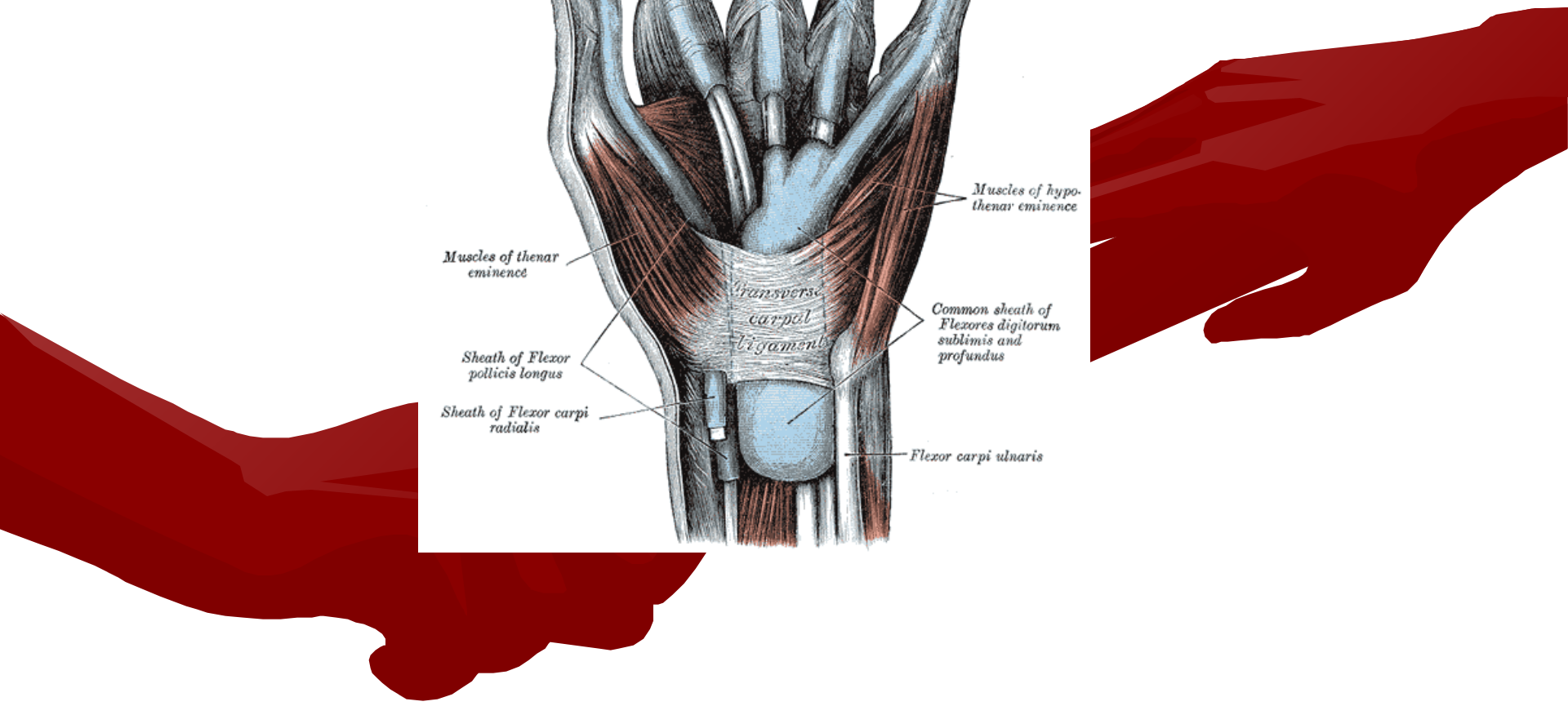
Sheath of Flexor carpi radialis

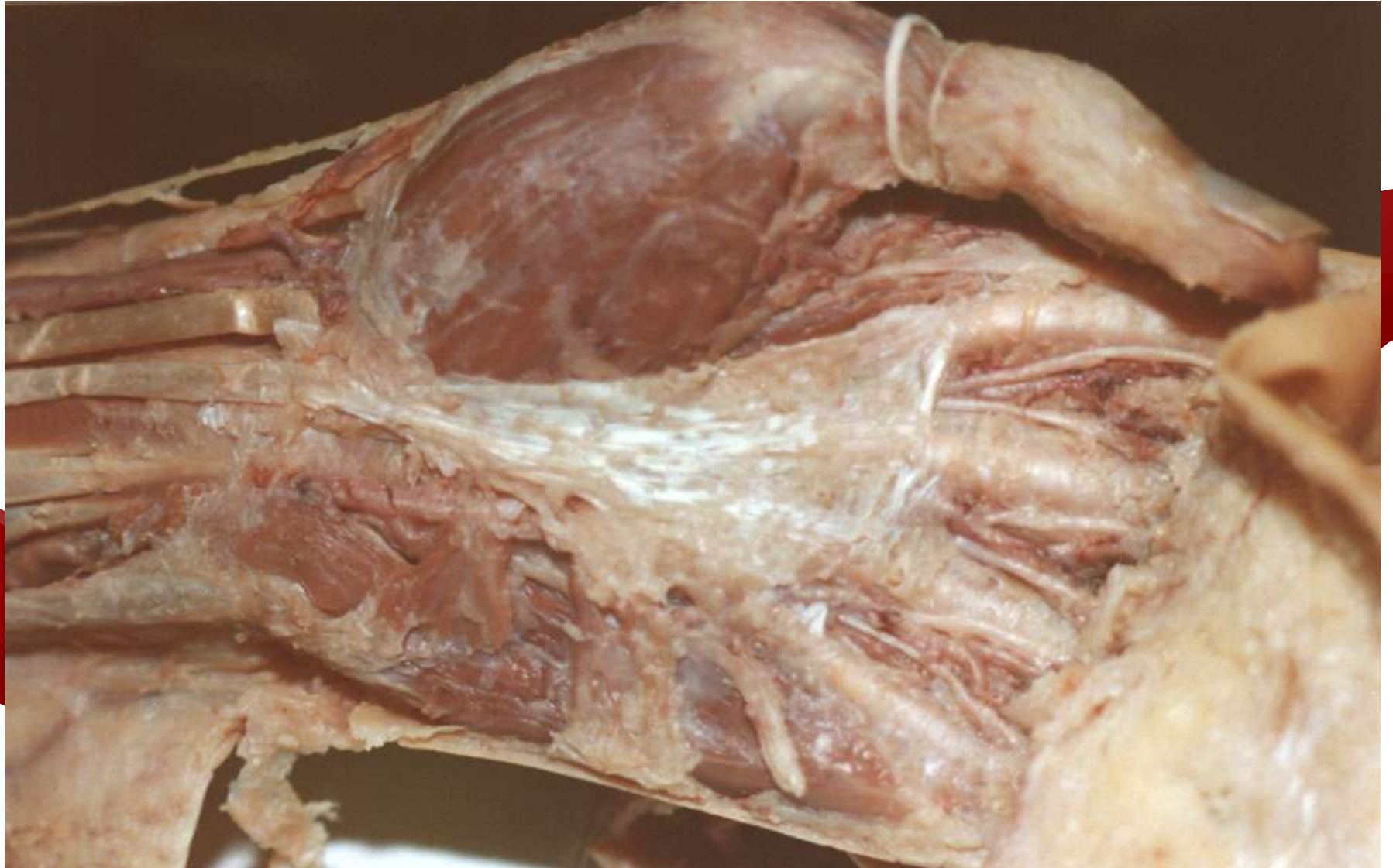transverse carpal ligament

Flexor carpi ulnaris

Muscles of hypothenar eminence

Common sheath of Flexores digitorum sublimis and profundus






Bones most often injured

-
-
-
-
-


- Pharynxes

al snuffbox)

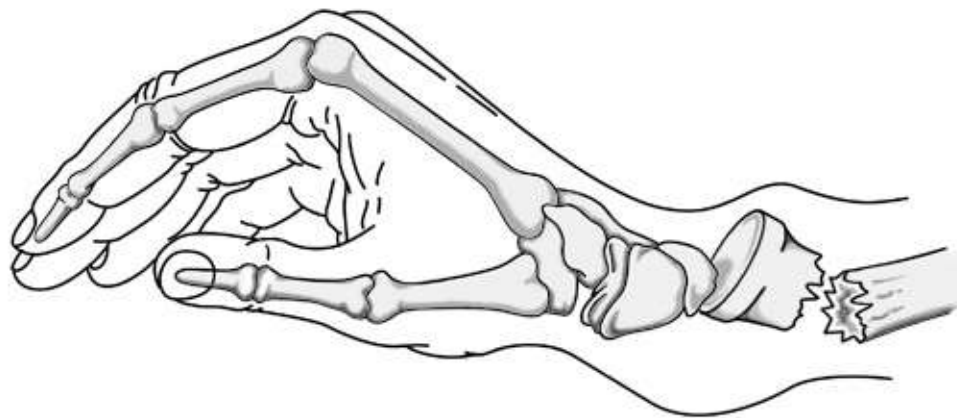

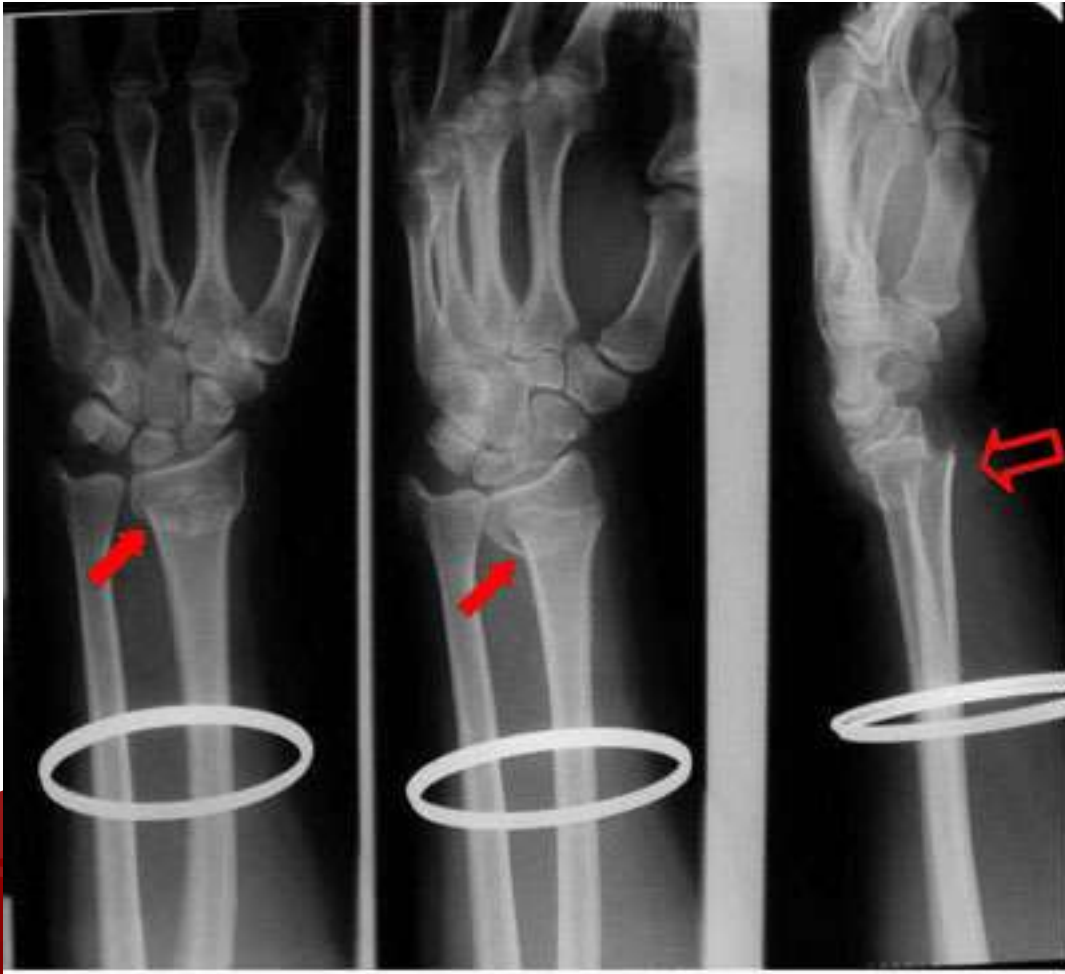Wrist Injuries

-
-
-
-

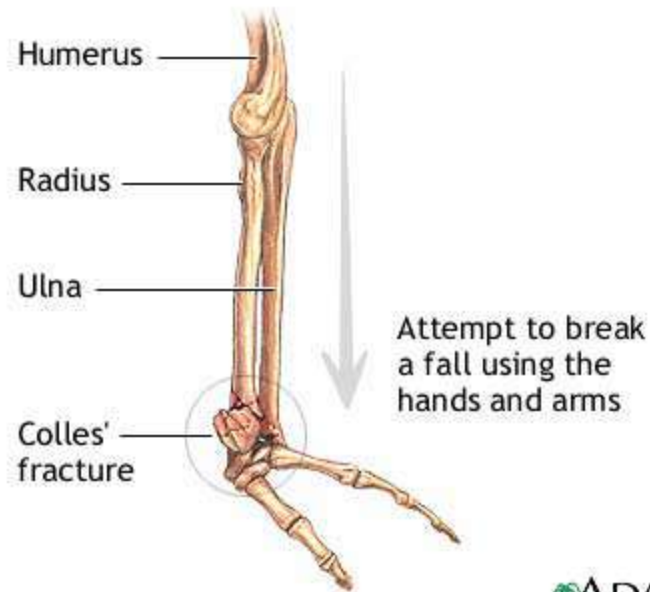


Colle's Fracture







Mechanism of Injury



S/S




Complications




Care

-
-
-
-

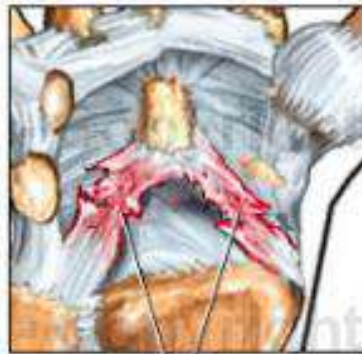
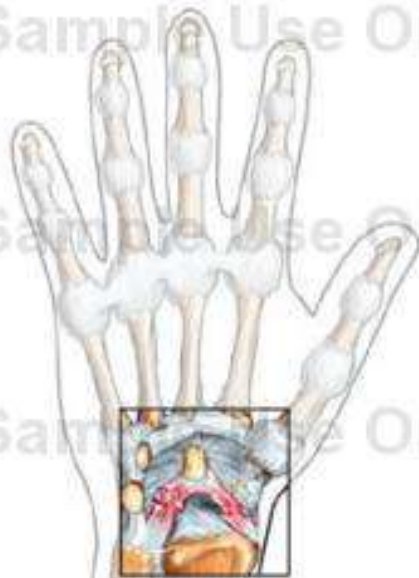

Wrist Sprain

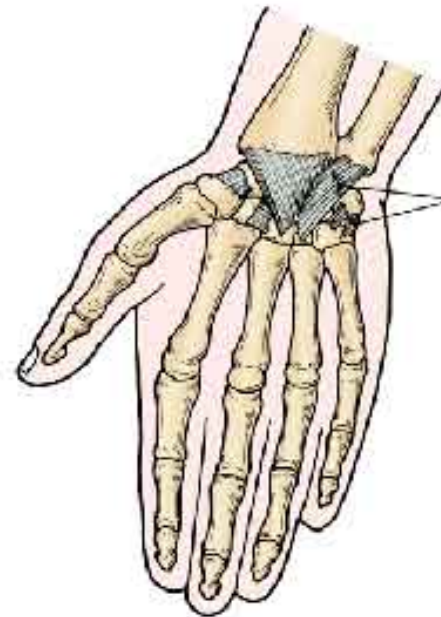


Wrist sprain


Wrist Sprain




Injury to the ligaments of the wrist



Example of injured ligaments in a wrist sprain



ted ROM



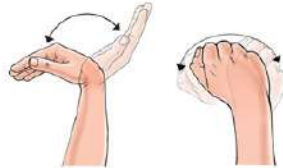
vere

ed ROM

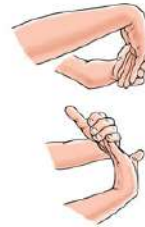apps

Treatment for wrist injuries

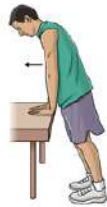Wrist Sprain Rehabilitation Exercises



Wrist range of motion



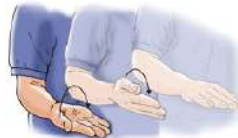Wrist stretch



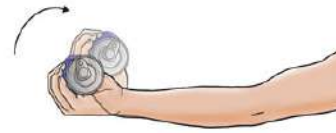Wrist extension stretch



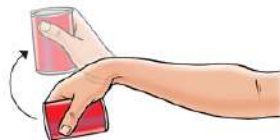Wrist flexion stretch



Forearm pronation and supination



Wrist flexion




Wrist extension



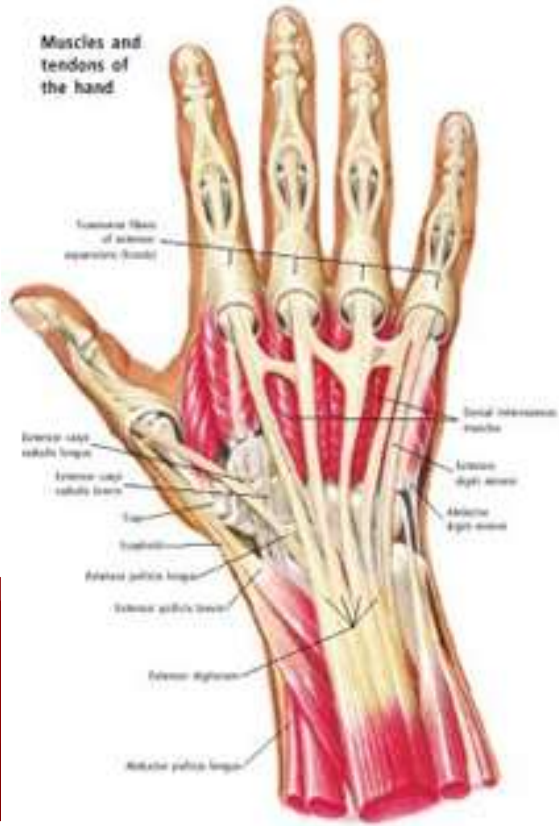Grip strengthening

© 2007 RelayHealth and/or its affiliates. All rights reserved.

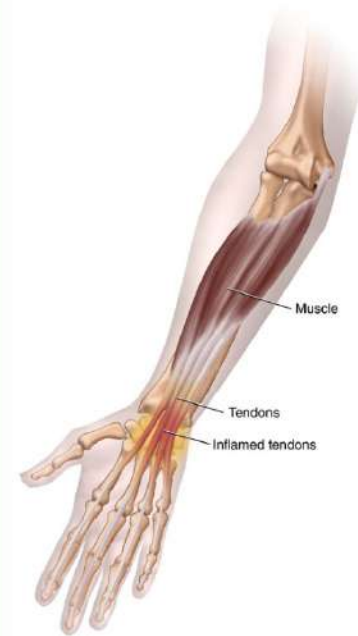Wrist Tendonitis




Muscles and tendons of the hand



Wrist Tendonitis





ensor tendons



-
-
-
-
-
-


- Splint
- Strengthening and B

Ganglion Cyst



... forced

... dorsum of 1



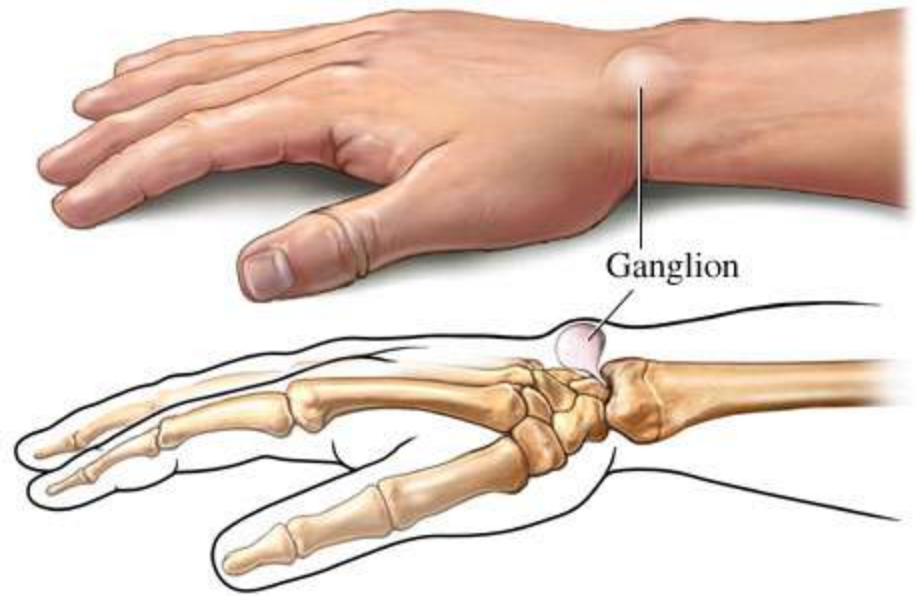
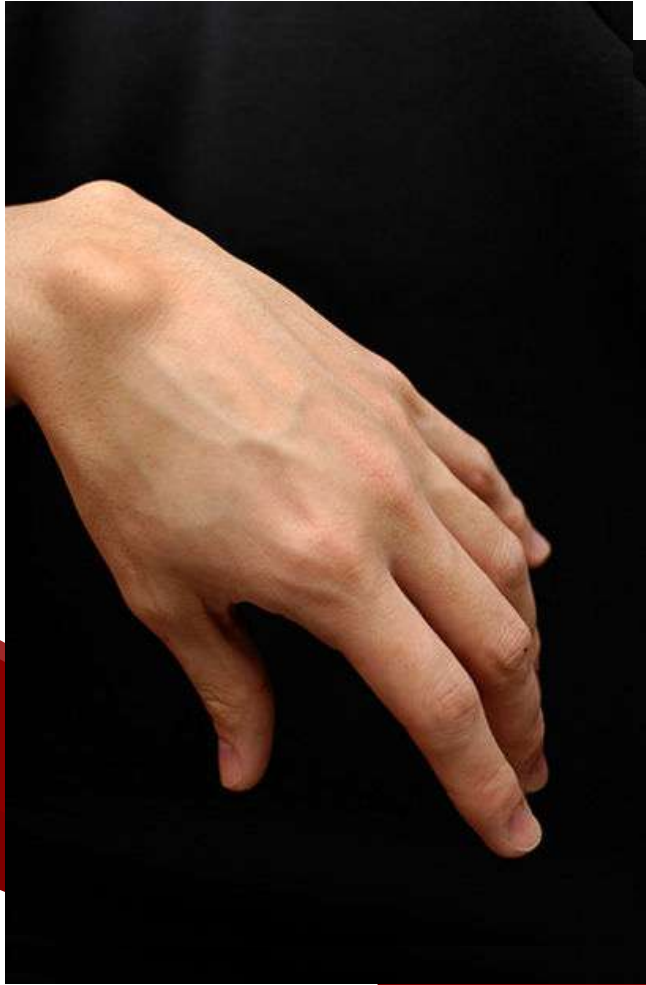Ganglion cyst

-
-
-
-

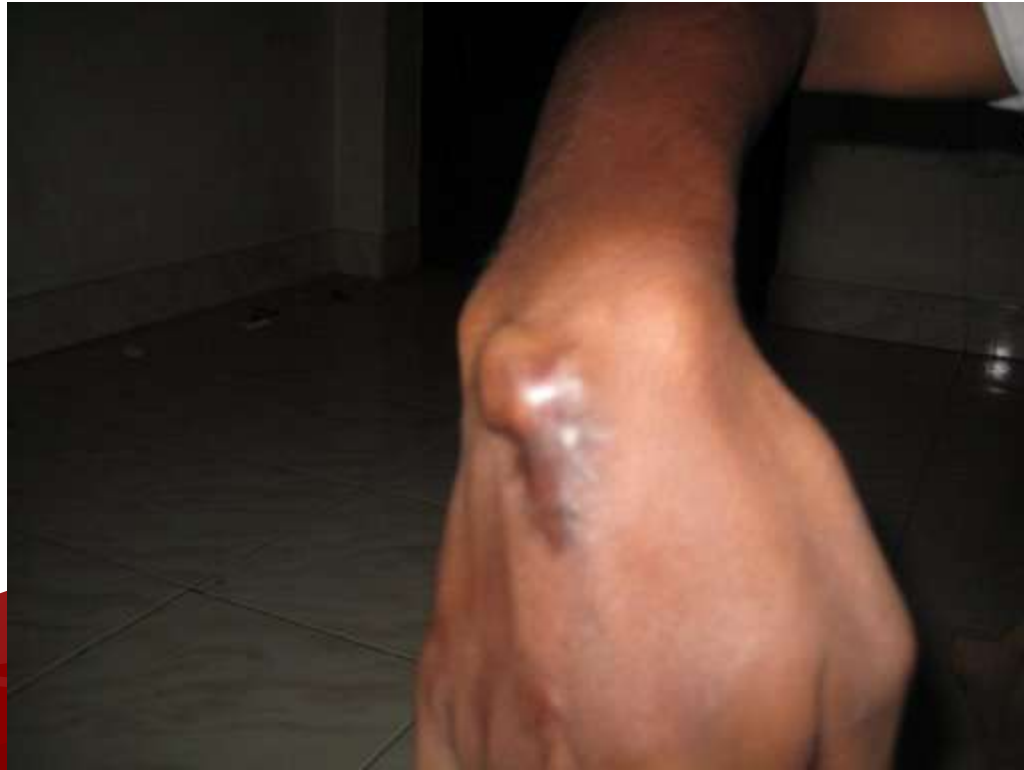

ard
ion of wrist

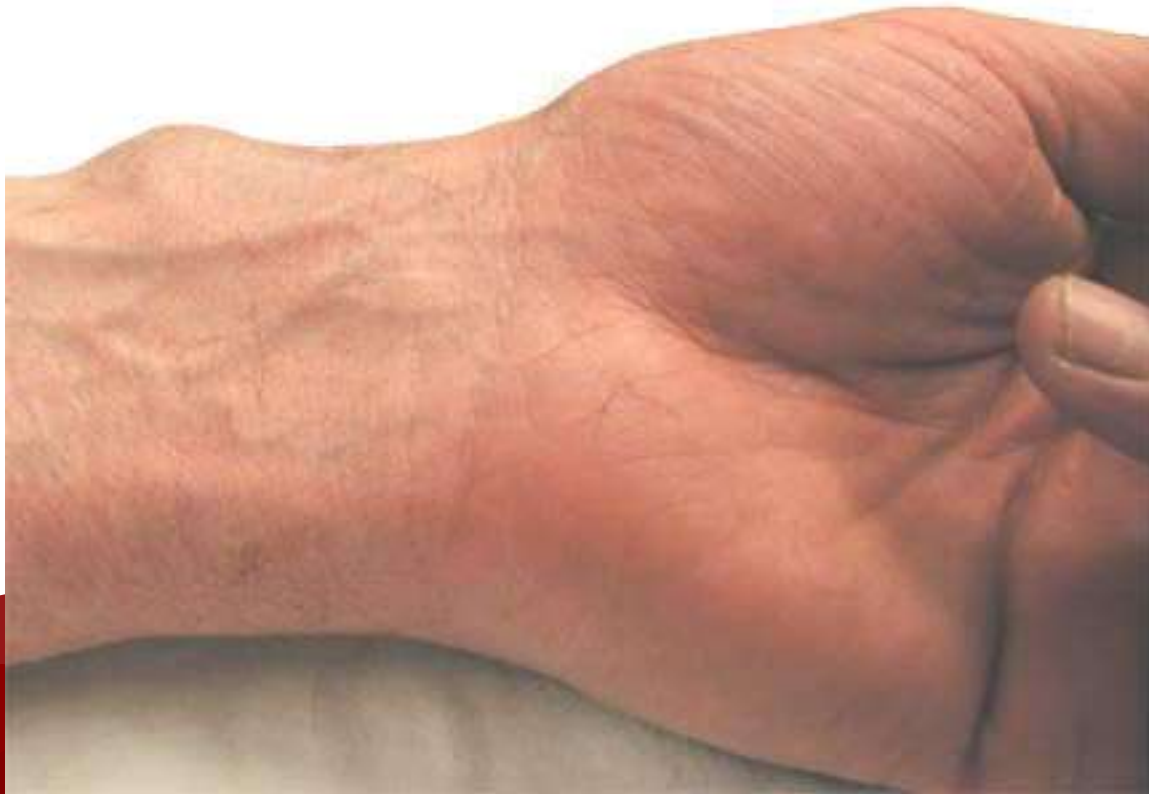Ganglion Cyst



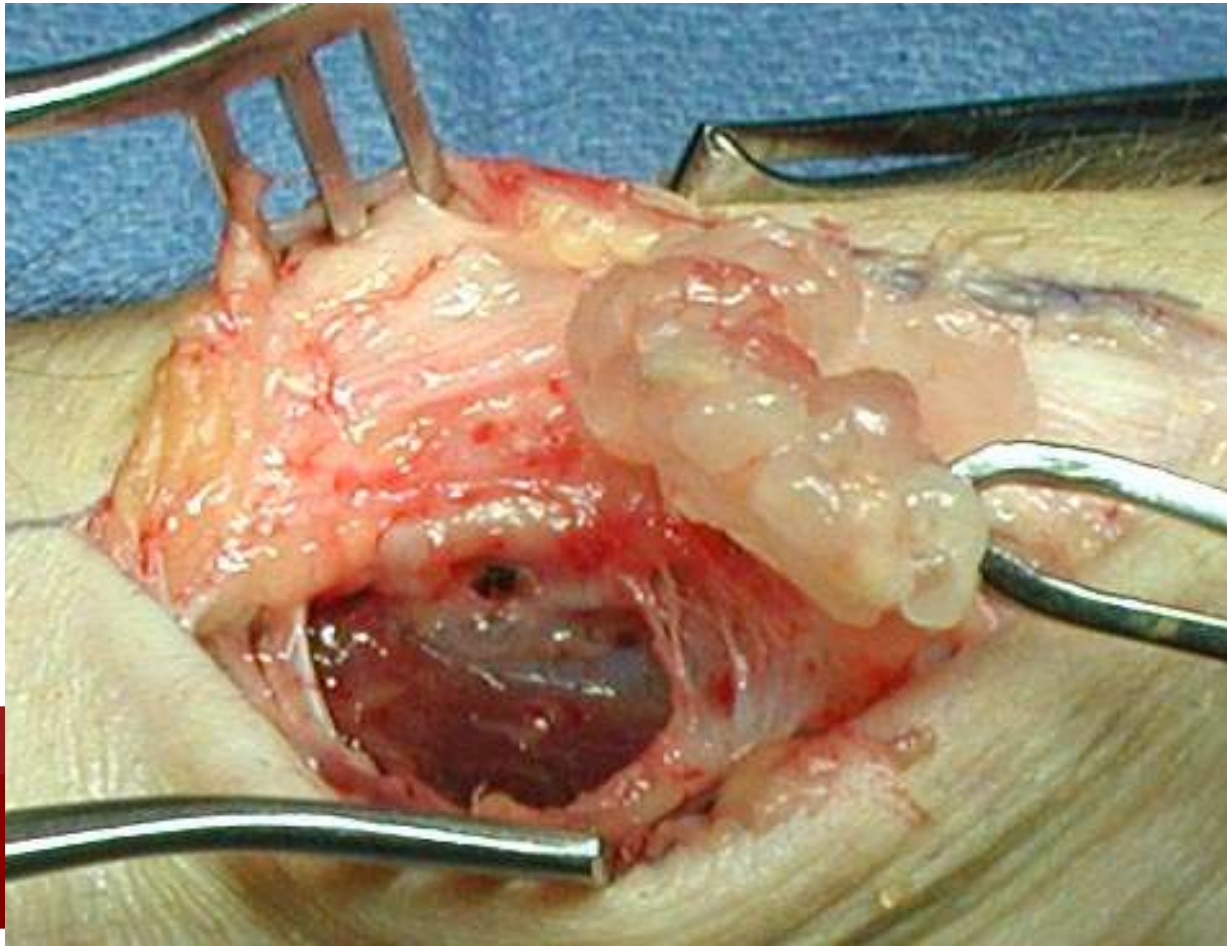
Ganglion cyst



Ganglion cyst



Ganglion cyst





•

•

•

•

•

•

will probably come back

Surgical removal

HIT IT WITH A P


ization followed


Hand injuries

-
-
-
-



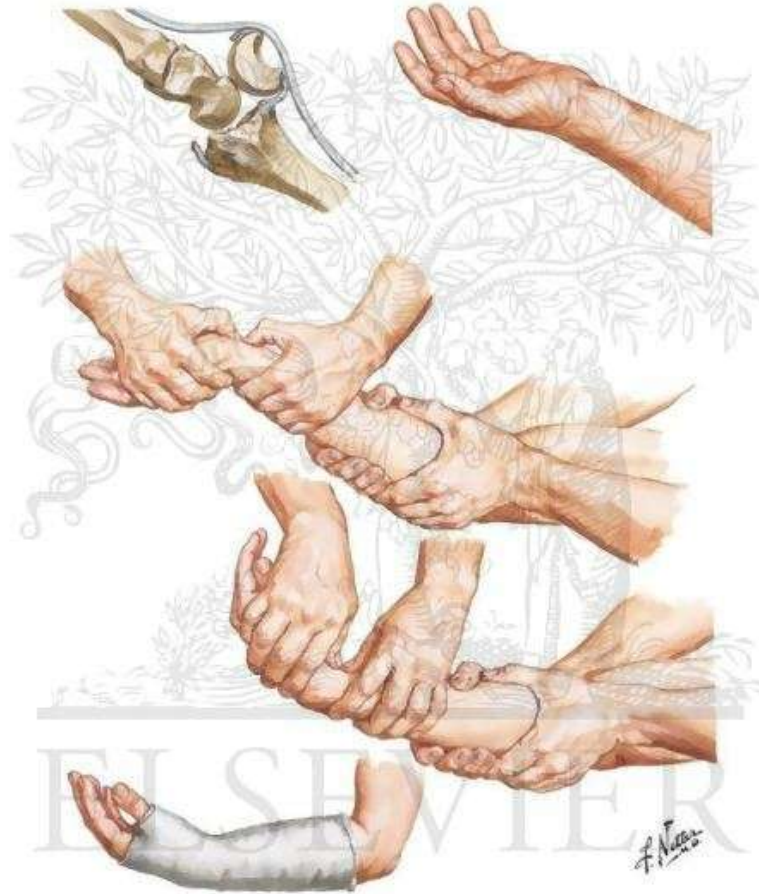
Dislocation of Lunate



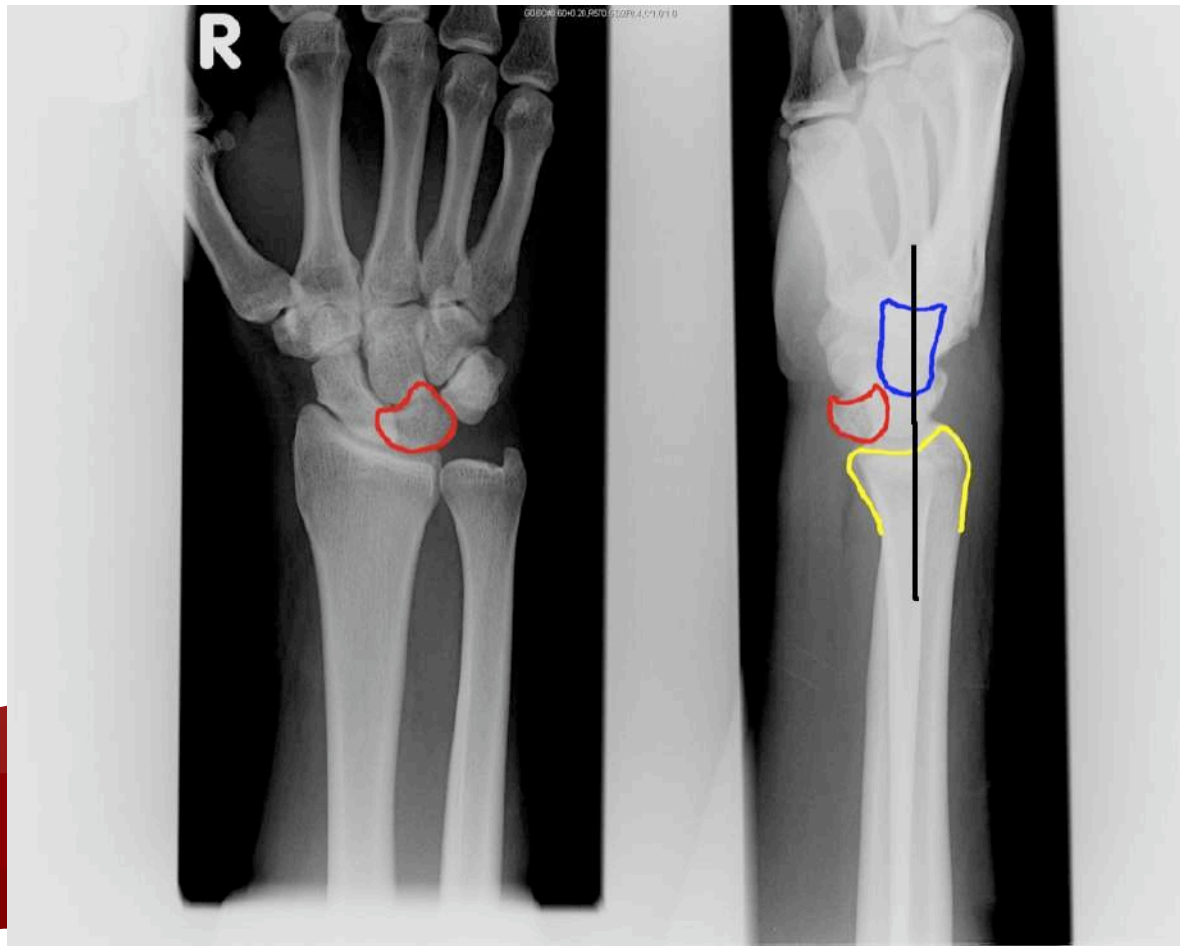



- deformity
- contracture of wrist
- contracture of fingers into flexion
- contracture of extensors due to pressure of cast on median nerve

Lunate dislocation



Lunate Dislocation





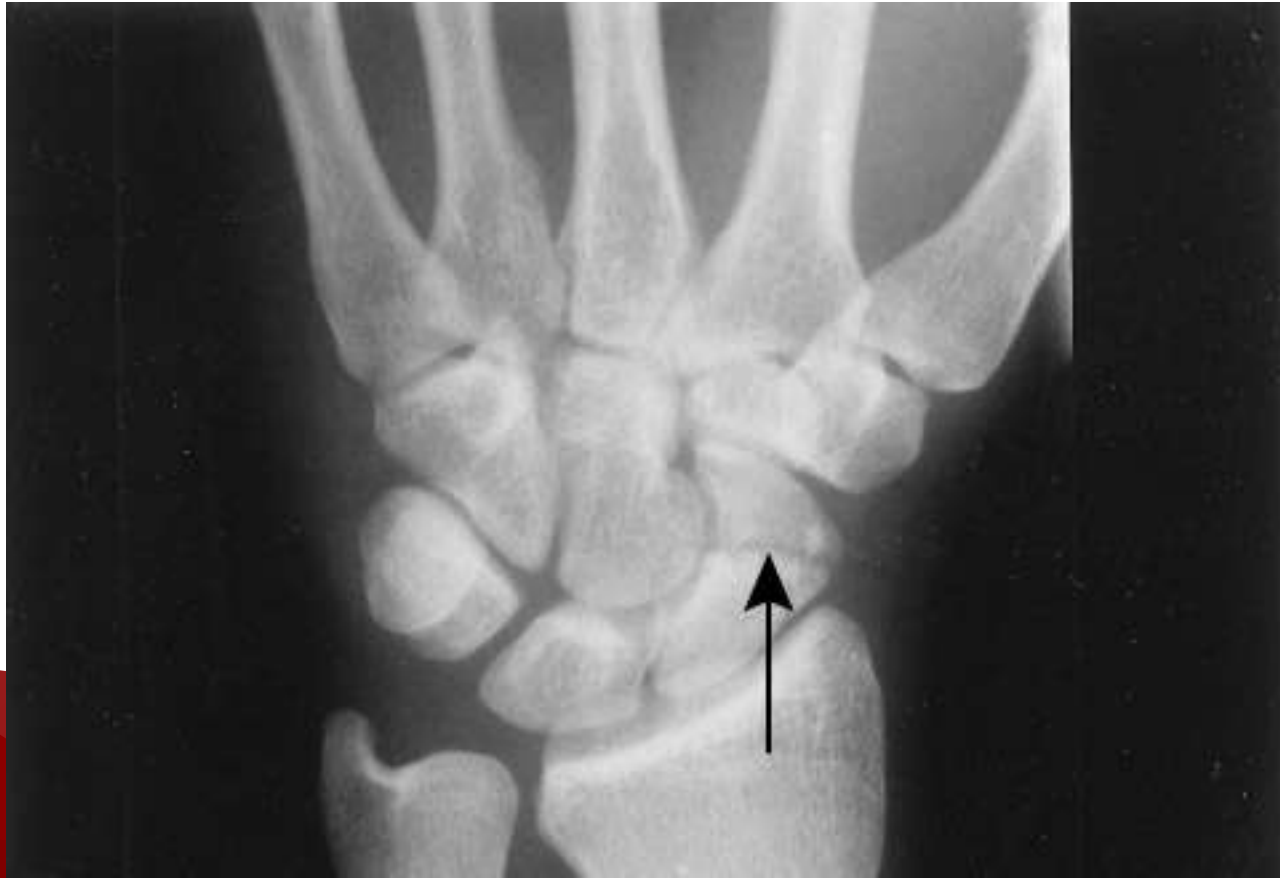
Scaphoid Fracture

-
-
-

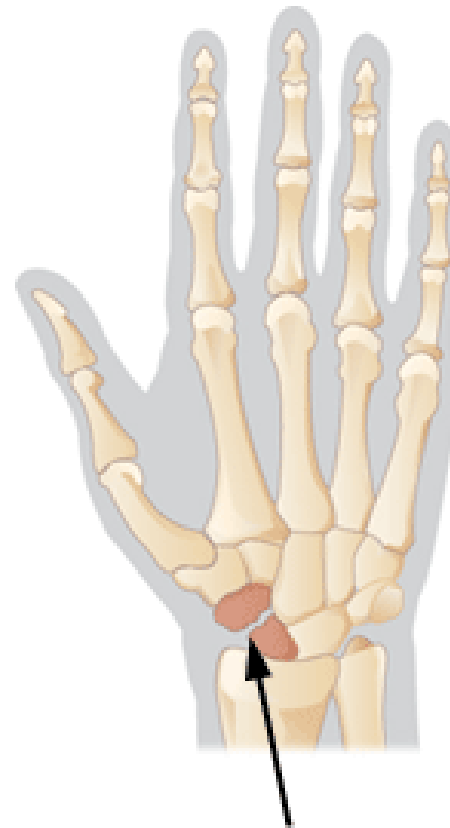
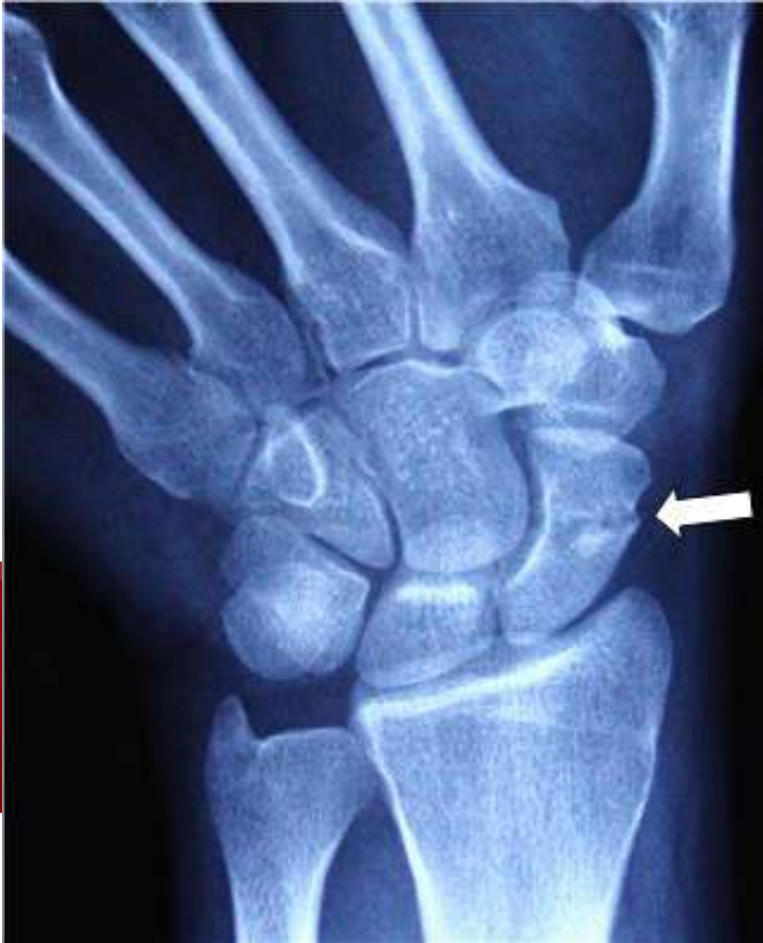



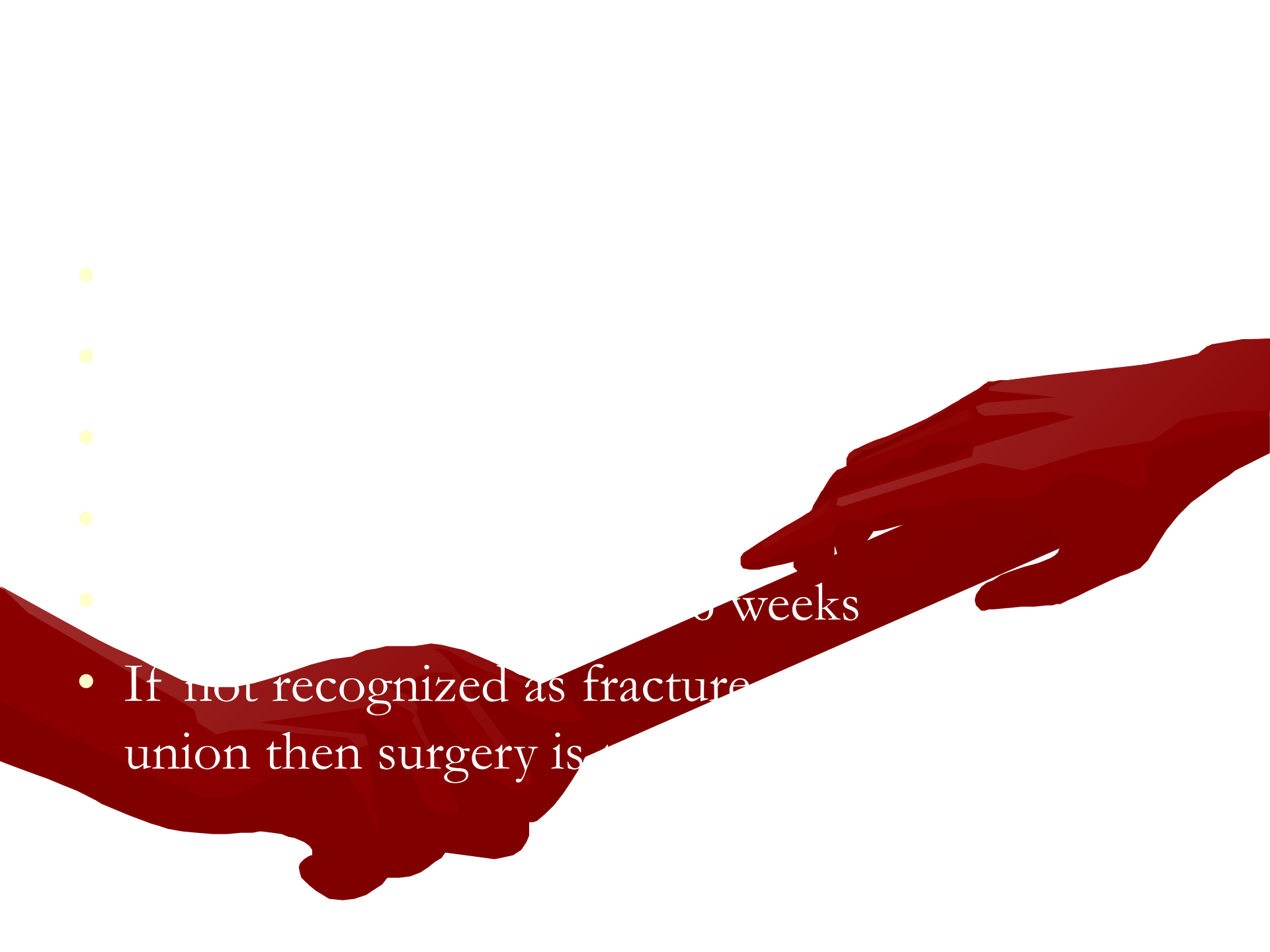Scaphoid fracture



Scaphoid fracture




Scaphoid Fracture



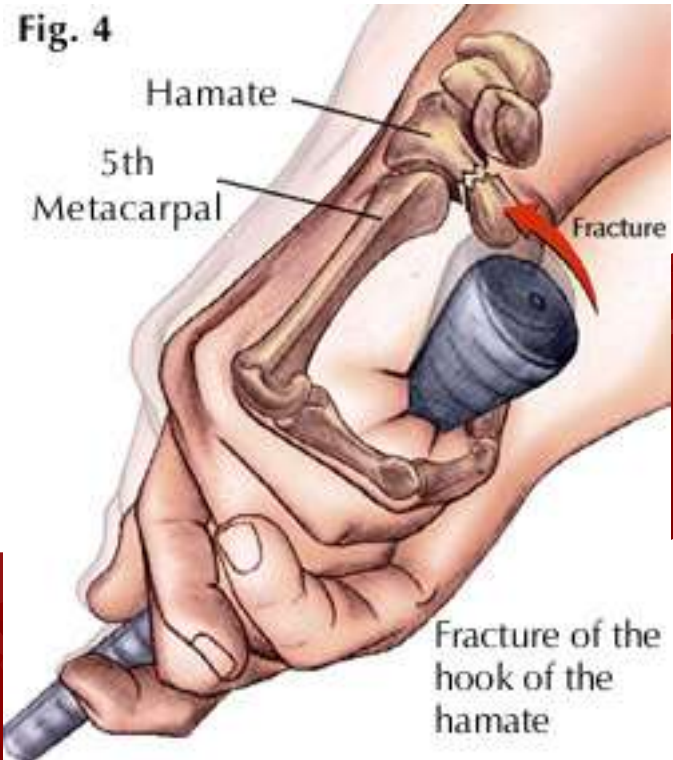
6 weeks

- If not recognized as fracture union then surgery is

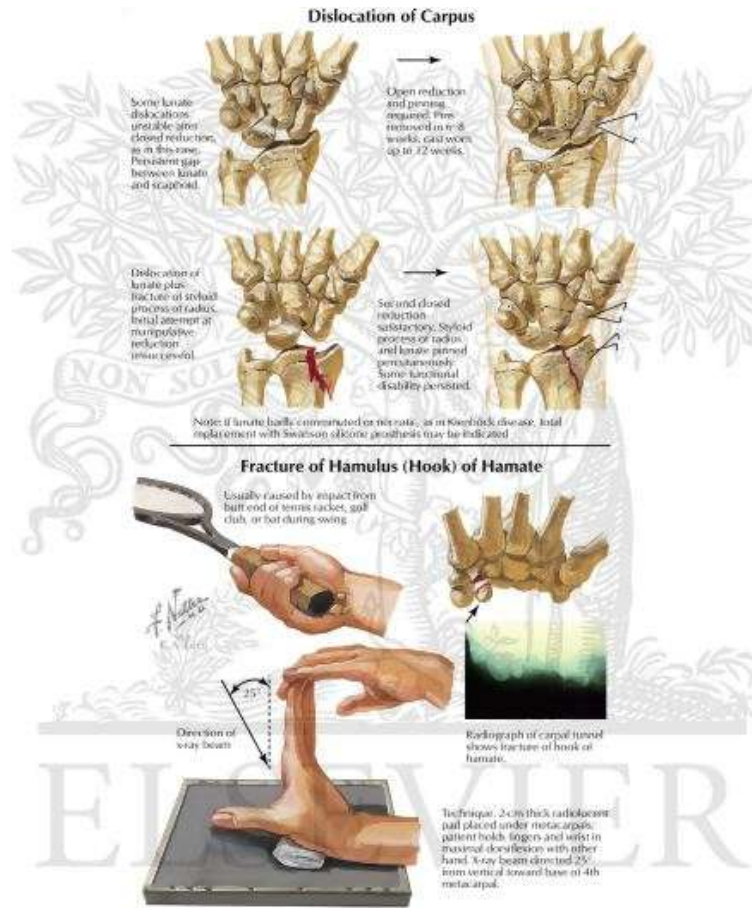
Hamate Fracture


- Hamate fracture
 - Common in golfers
 - Sports implement
 - Golf club
 - Golf club
 - Golf club
- 
- An illustration of a hand holding a golf club shaft. The hand is rendered in a dark red color. A red fracture line is shown on the hamate bone at the base of the fifth metacarpal. The text 'Hamate Fracture' is at the top. A list of items is on the left, with yellow dots and lines. The text 'Sports implement' is on the right, and 'Golf club' is repeated three times on the left.

Hamate fracture



Hamate fracture



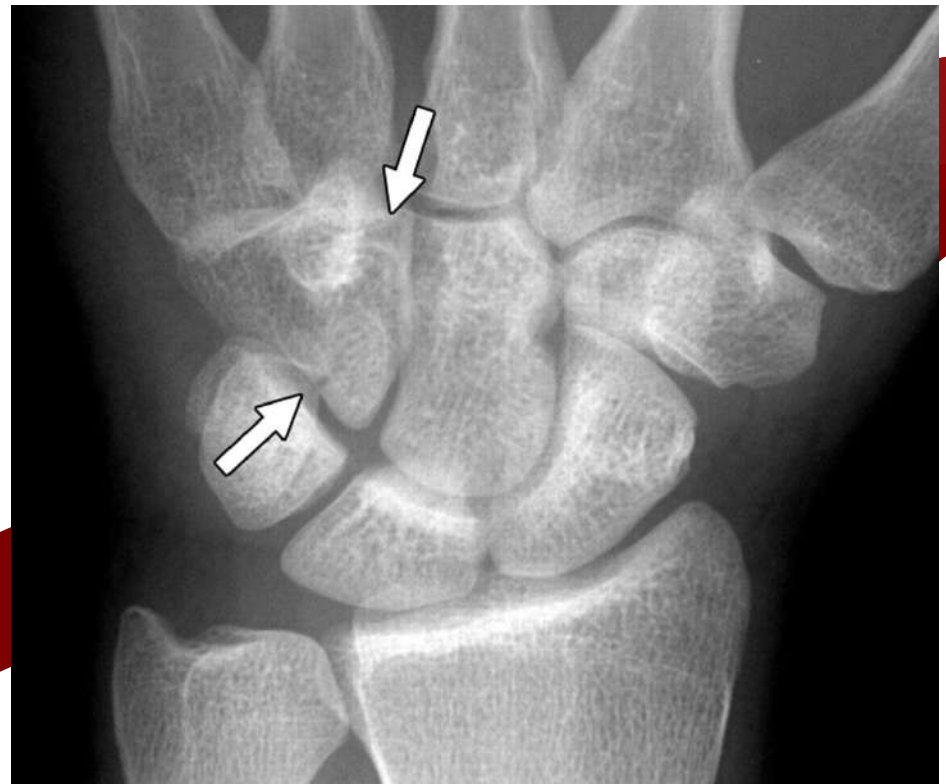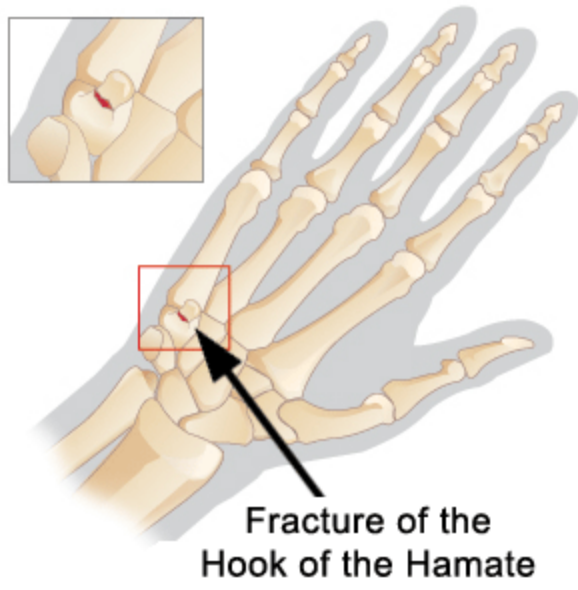



-
-
-
-
-
-

of ulnar nerve

es due to co

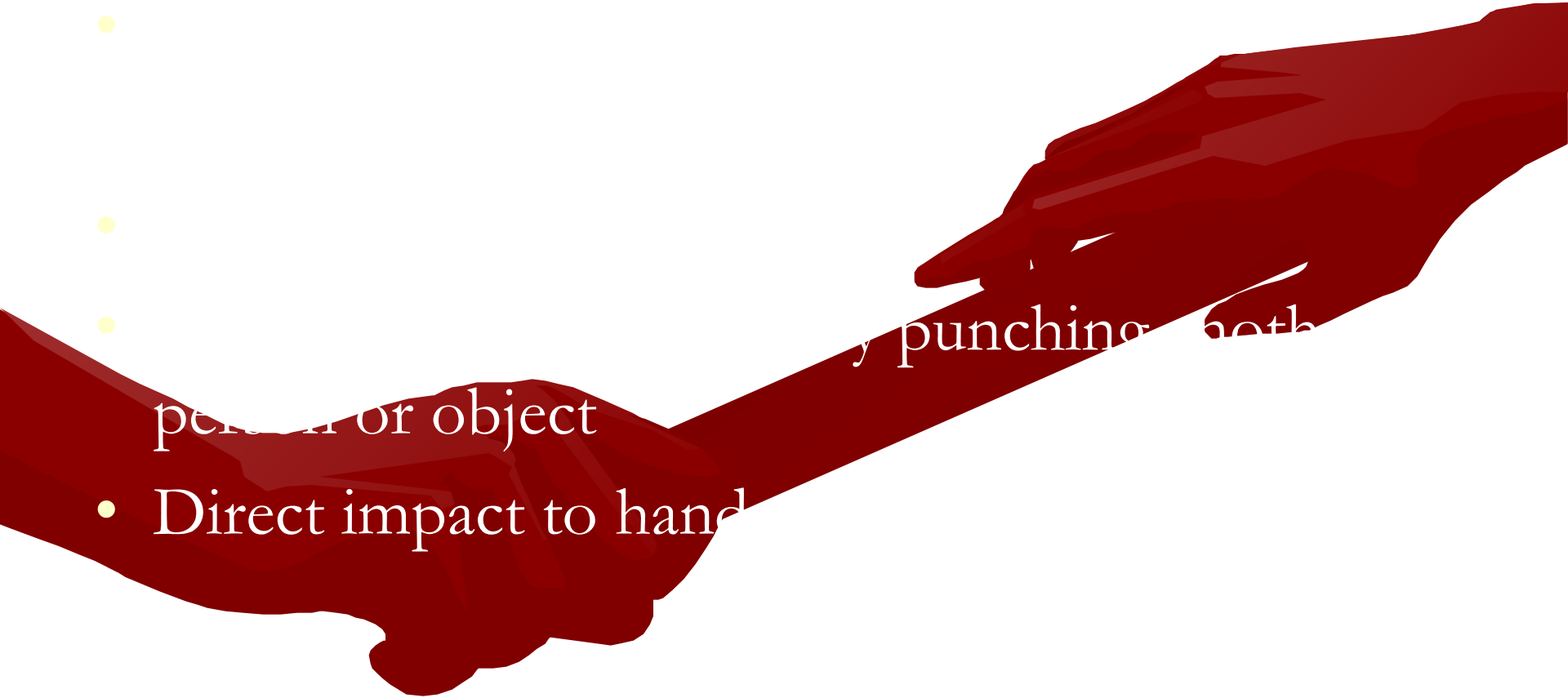
Hook of hamate fracture



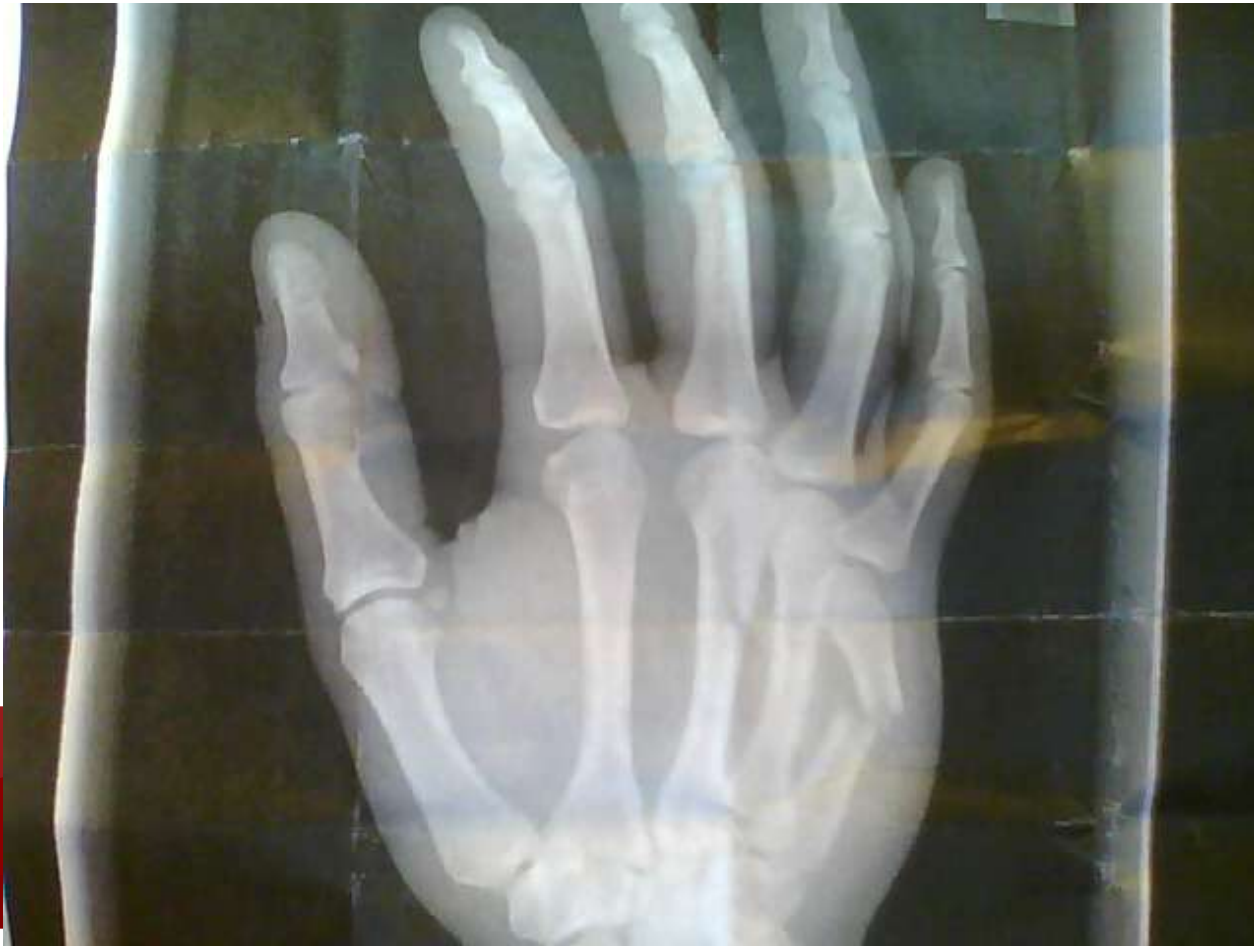

Metacarpal (Boxer's) Fracture

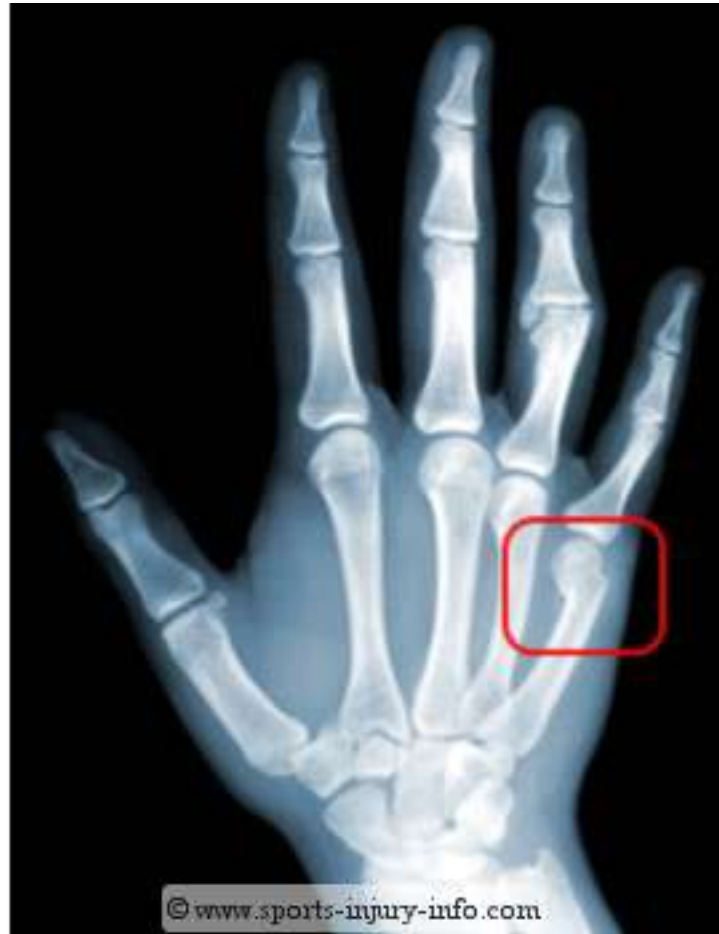- Common
- Caused by punching both
- Person or object
- Direct impact to hand




Boxer's fracture



Boxer's fracture



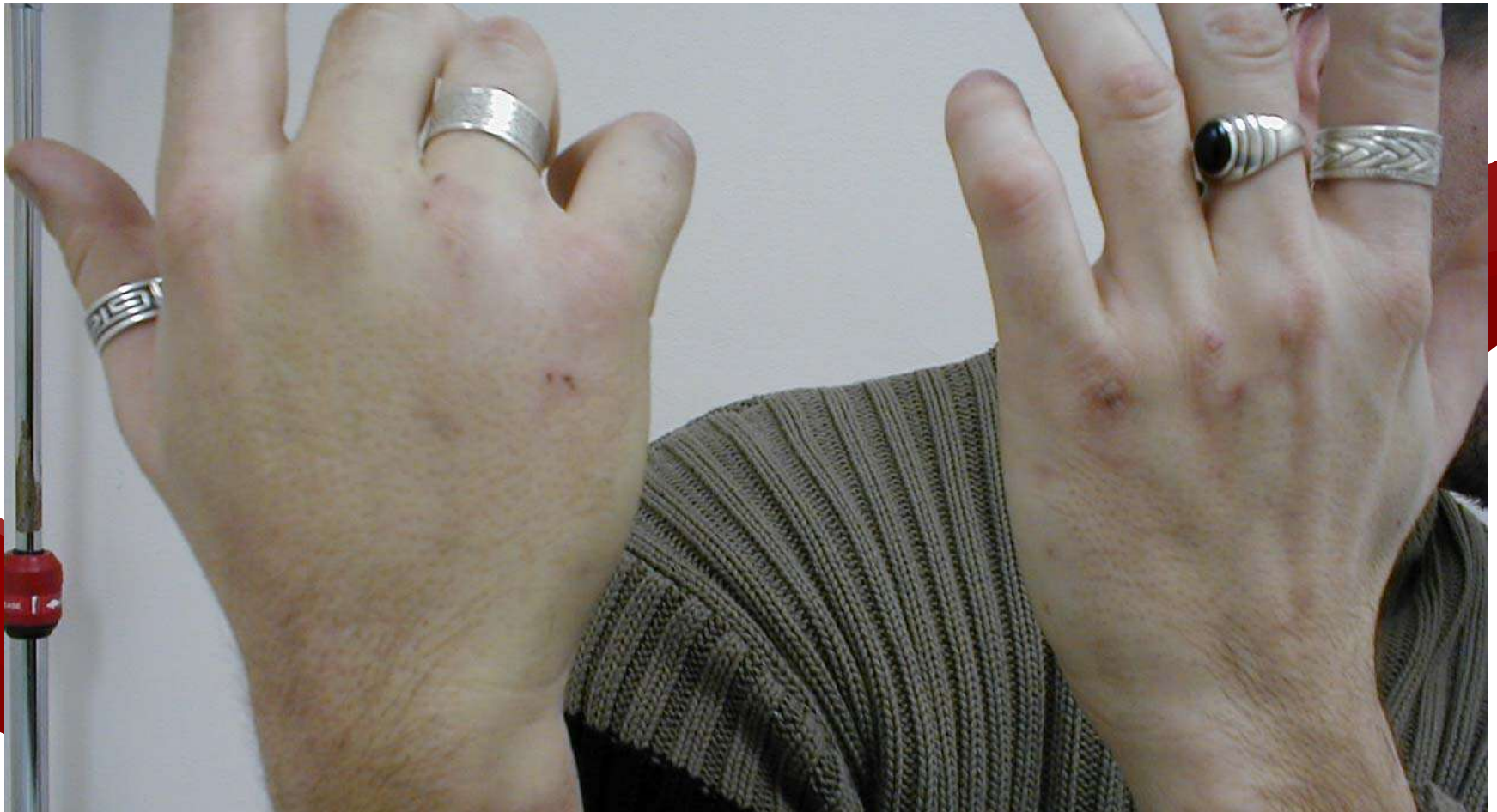

- Dislocation

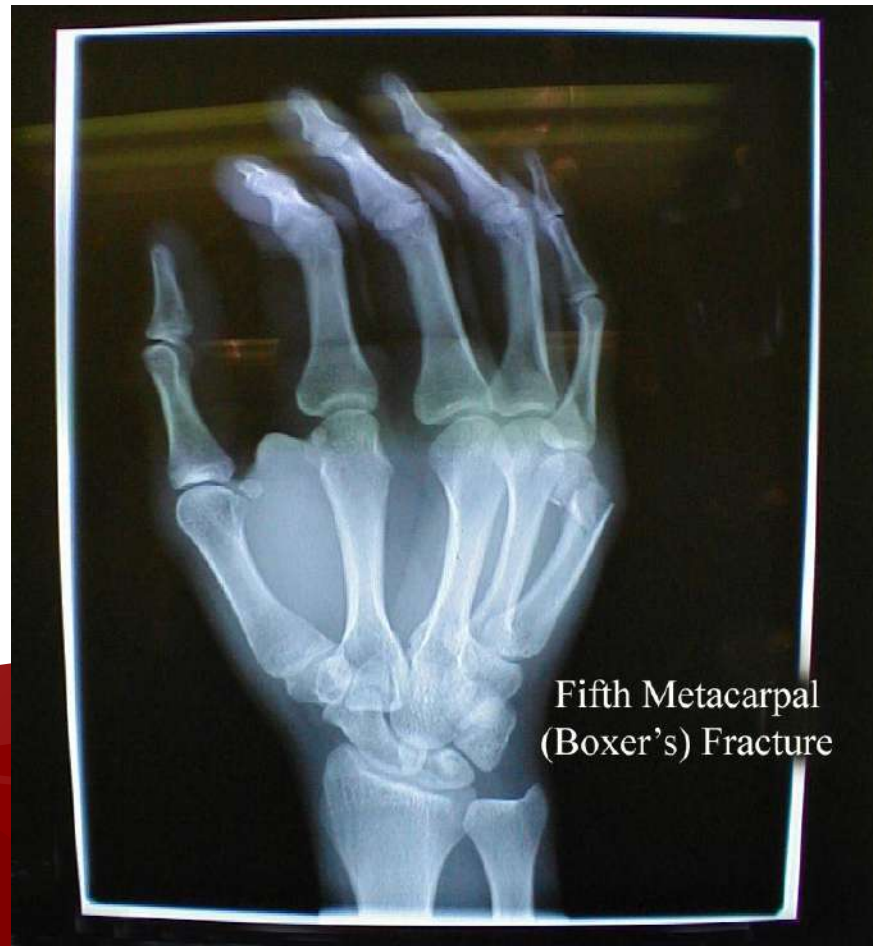- Pain with movement

Both
(s)

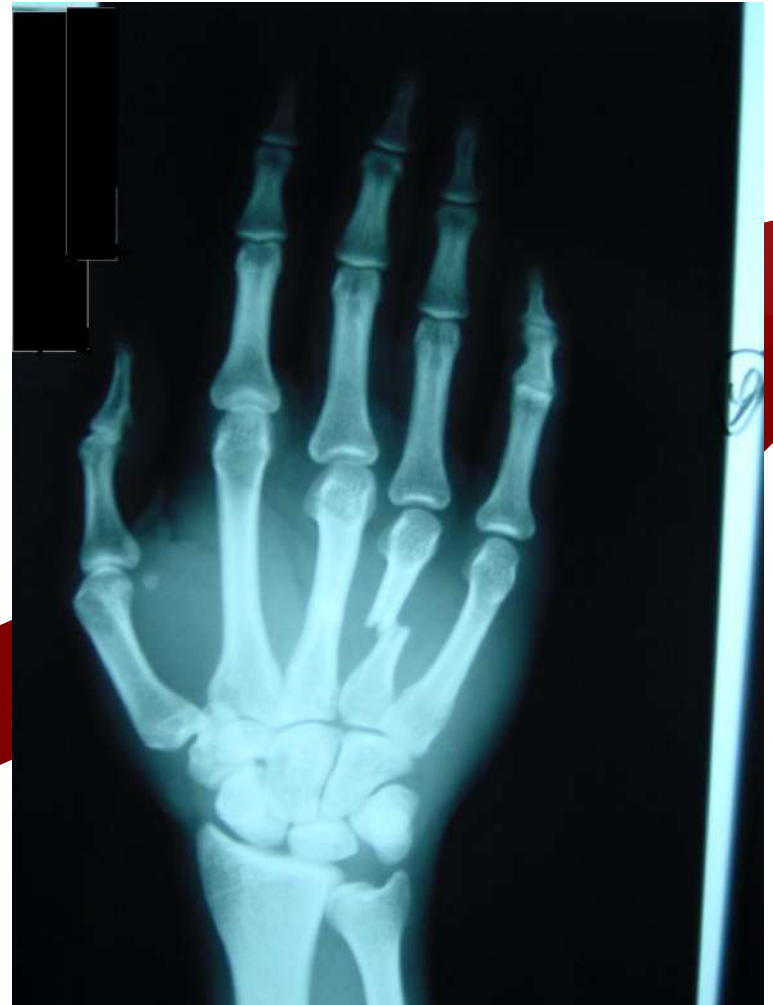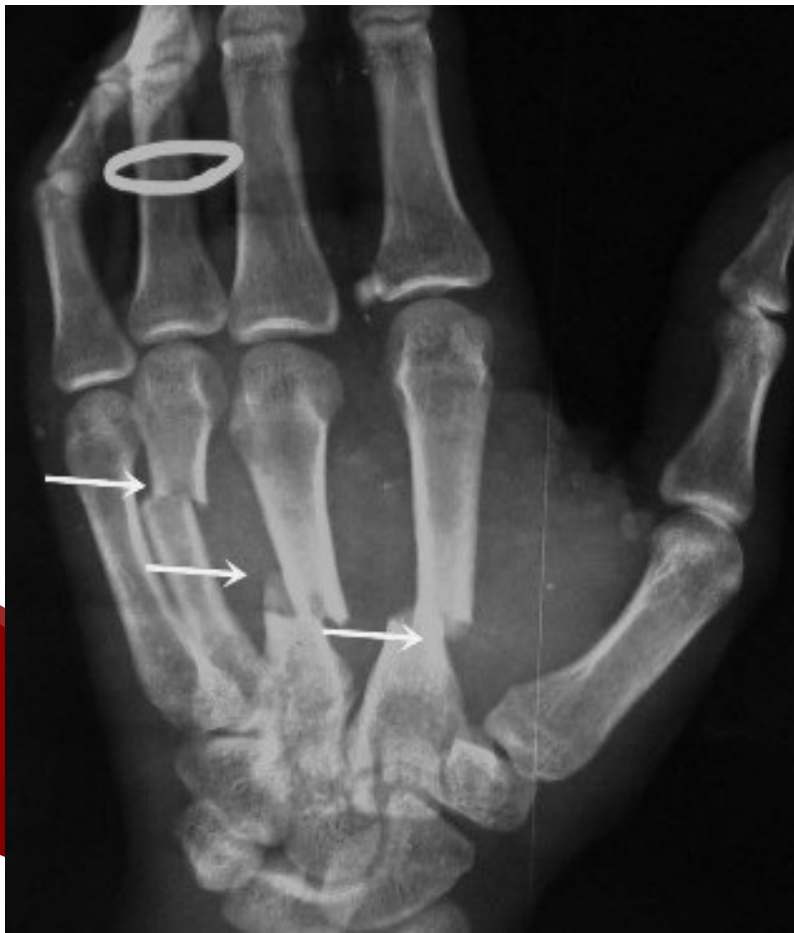Boxer's fracture




Boxer's fracture



Metacarpal fractures





(weeks)

Finger Injuries

-
-
-
-
-
-

- Sprain
- Subungual hematoma




Mallet Finger



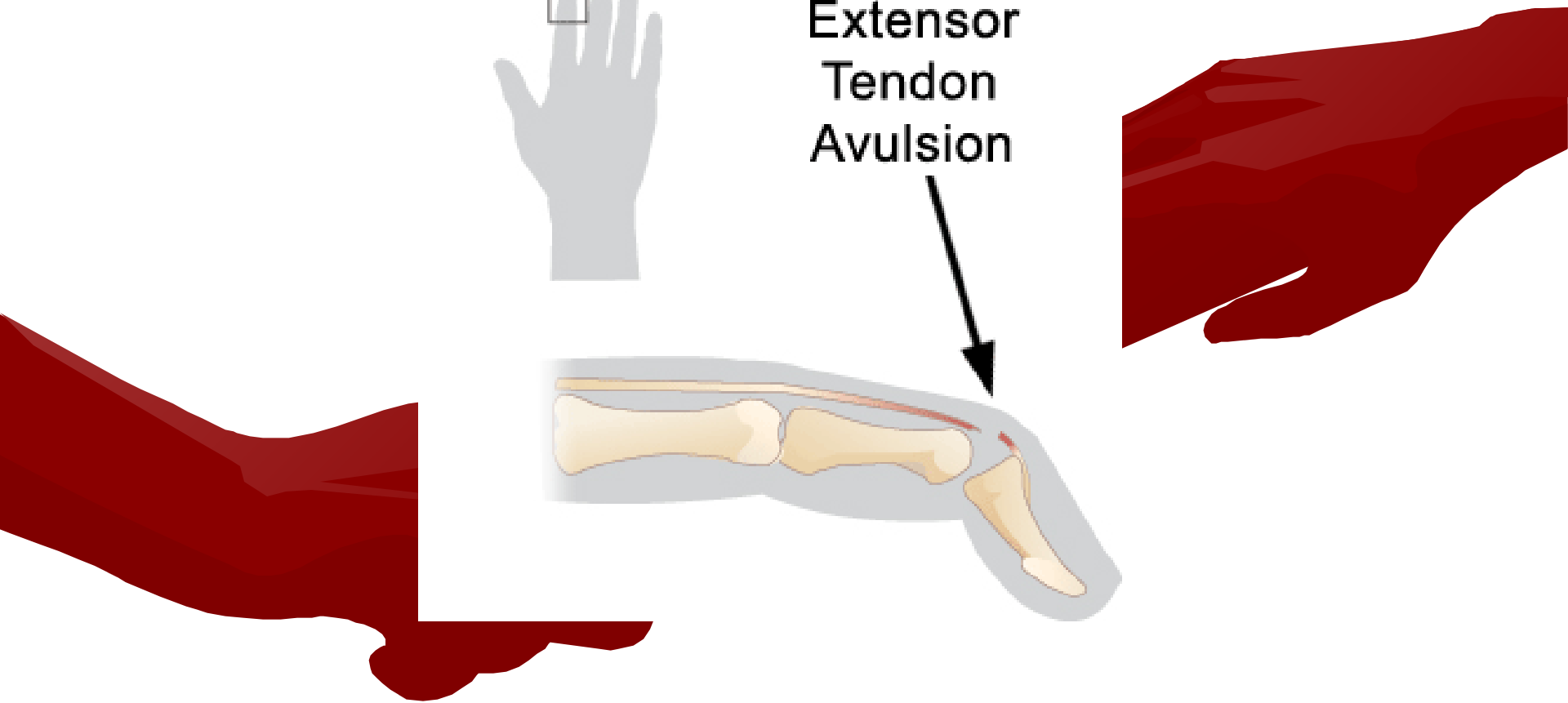
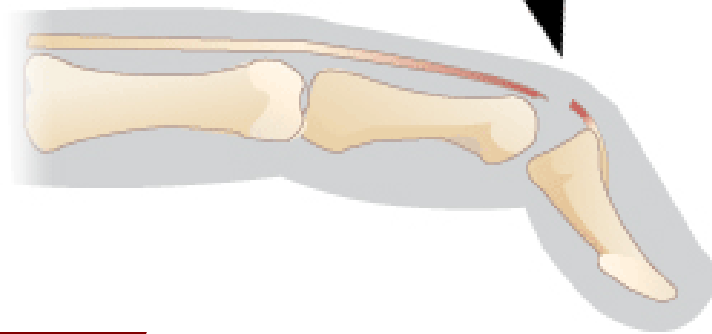
...ing
ion at the

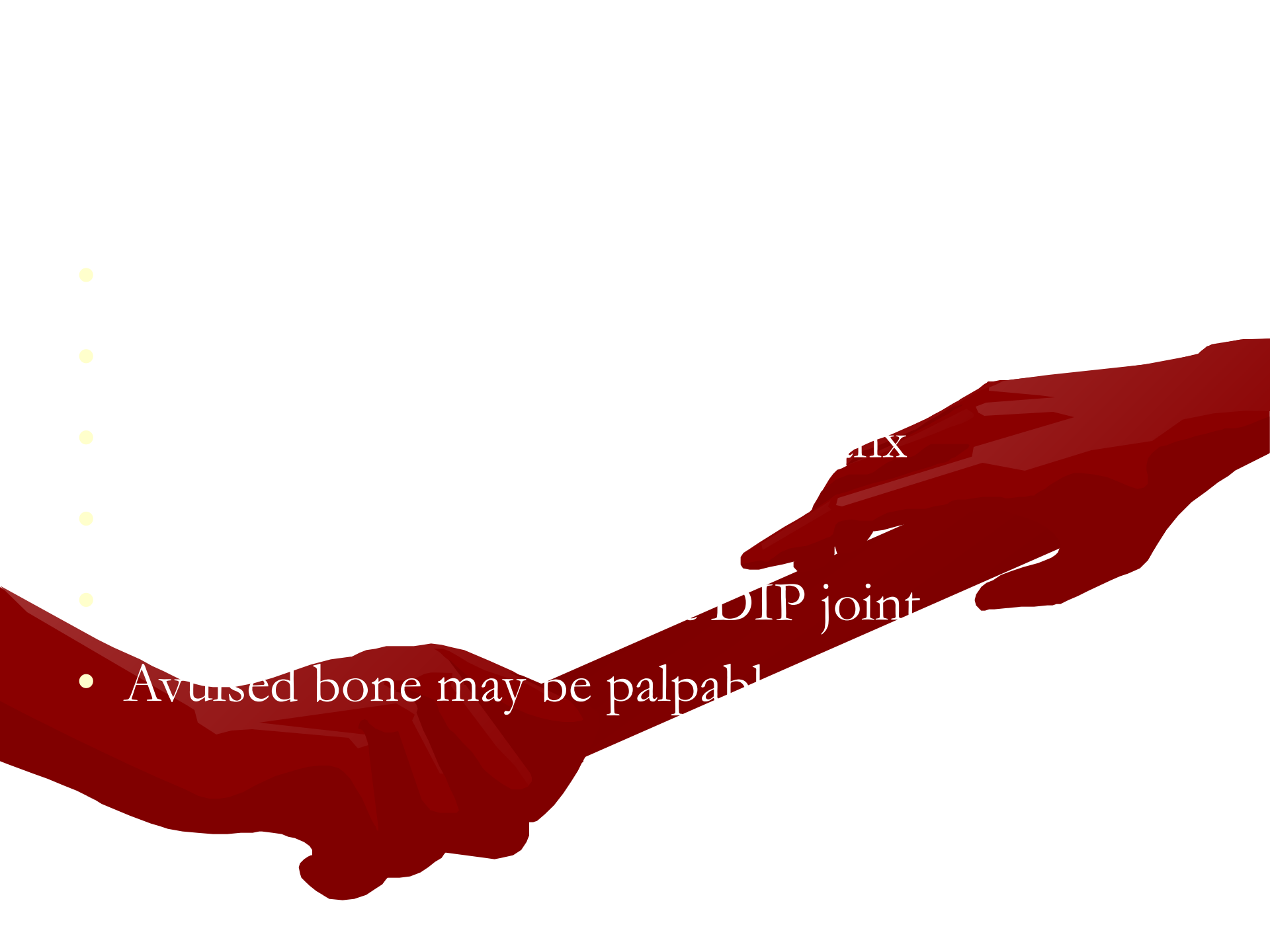... as well

Mallet finger



Extensor
Tendon
Avulsion





•

•

•

•

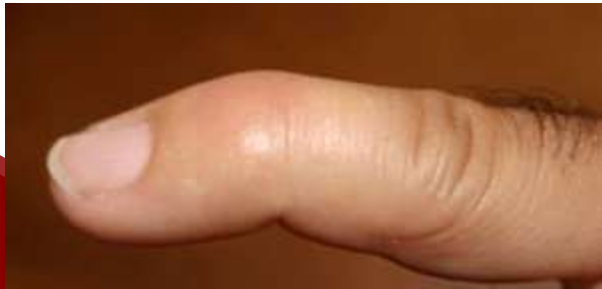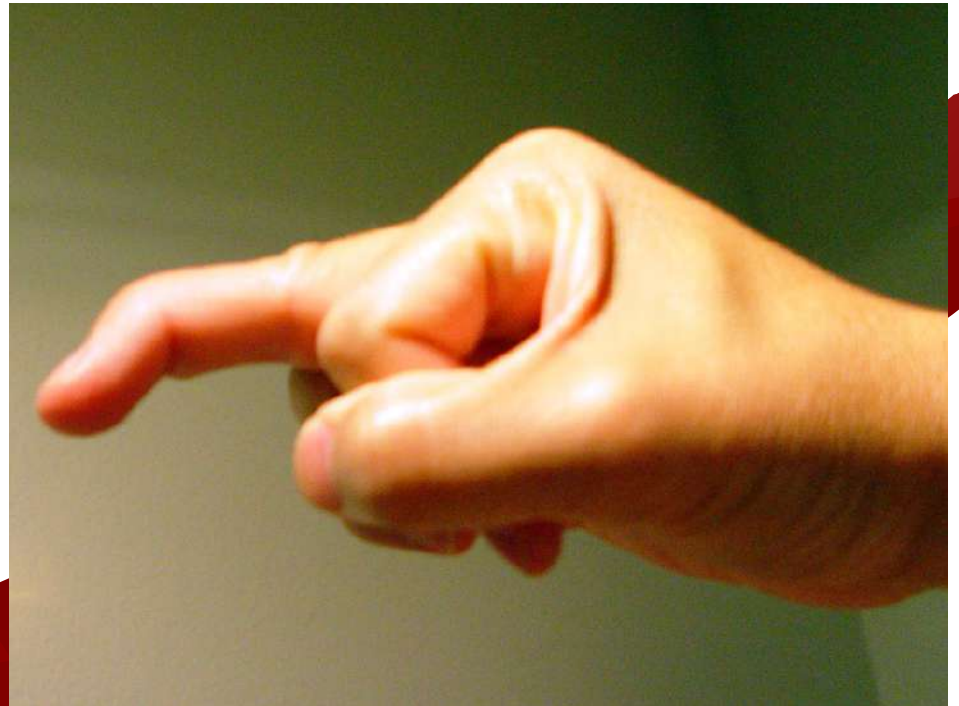
•


- Avulsed bone may be palpable

11X

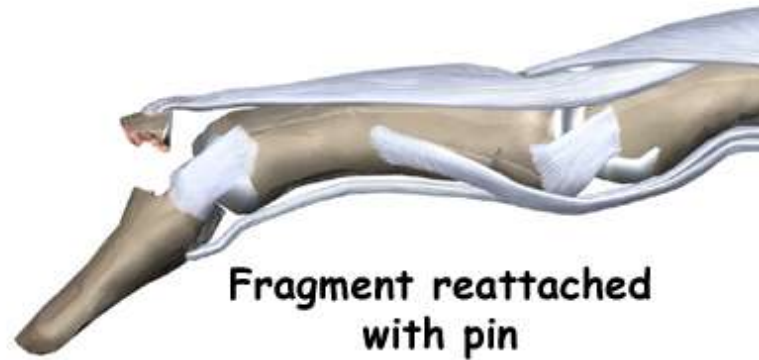
DIP joint

Mallet finger

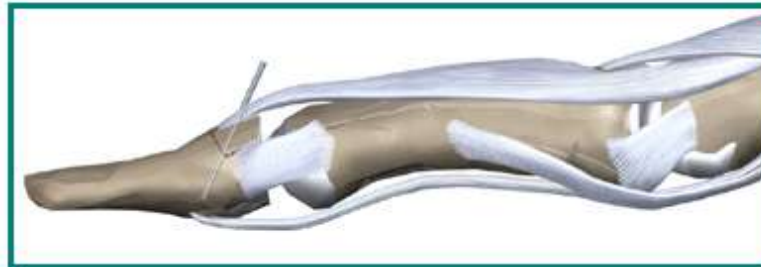



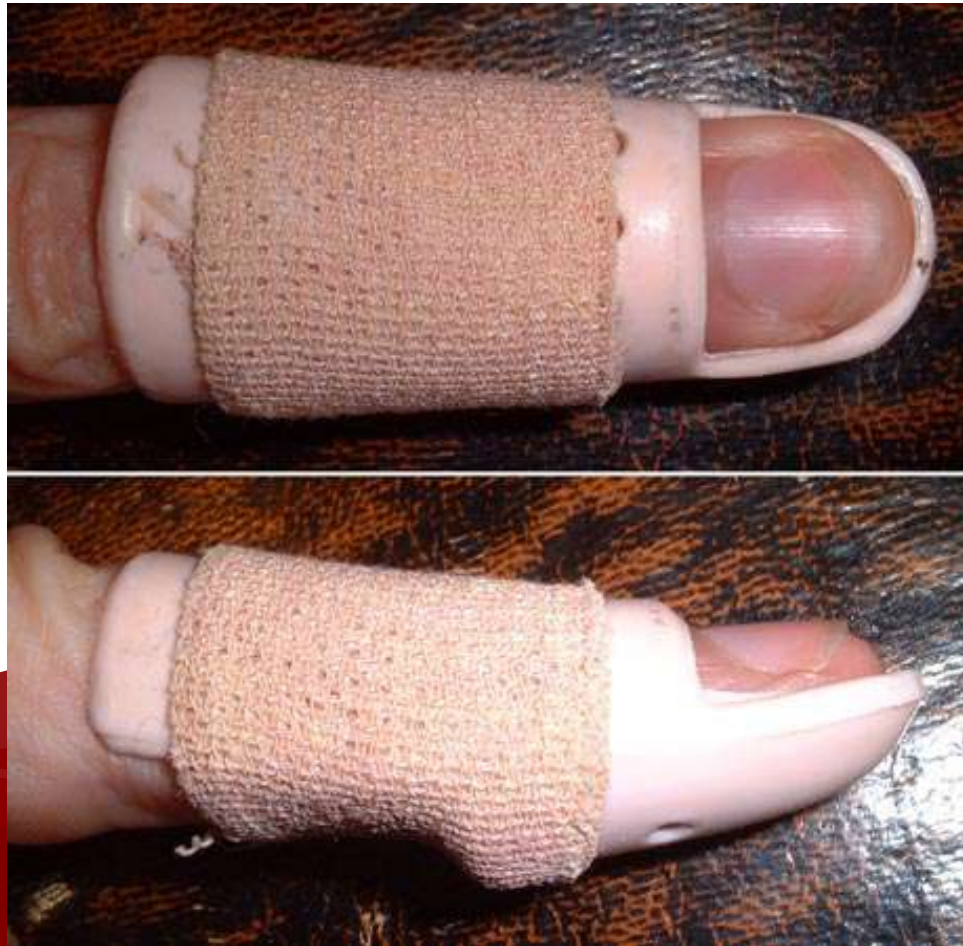Mallet finger



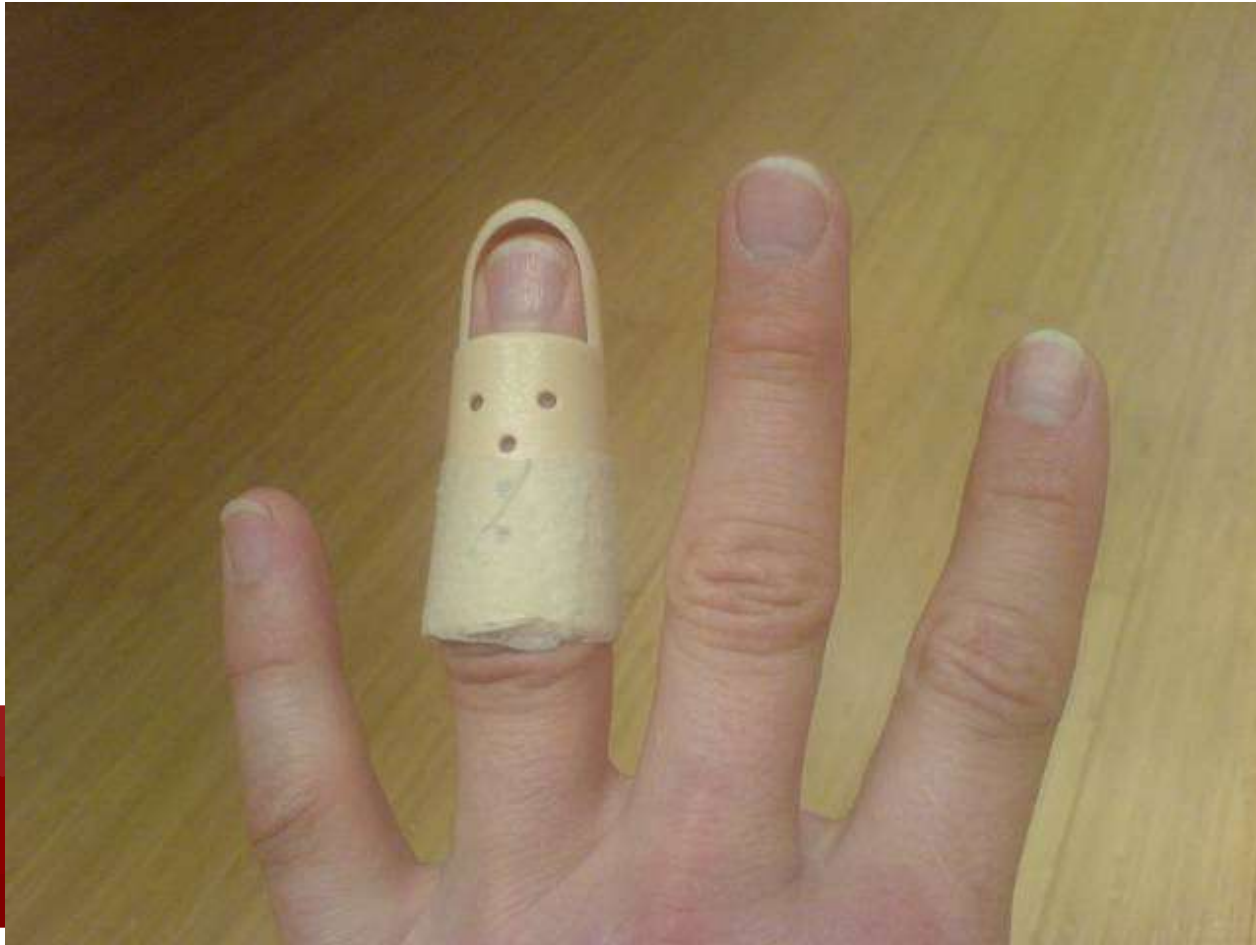Fragment reattached
with pin



Mallet finger-stack splint




Stack splint

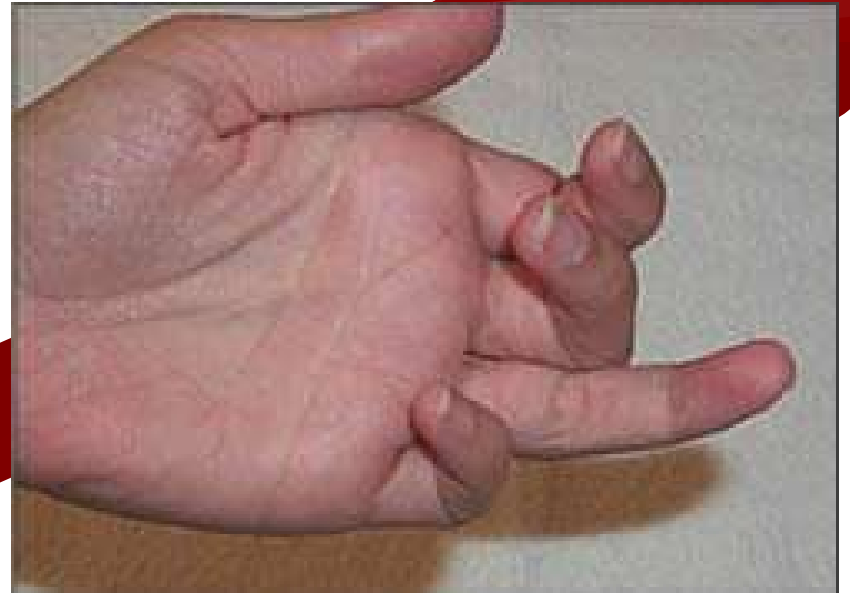
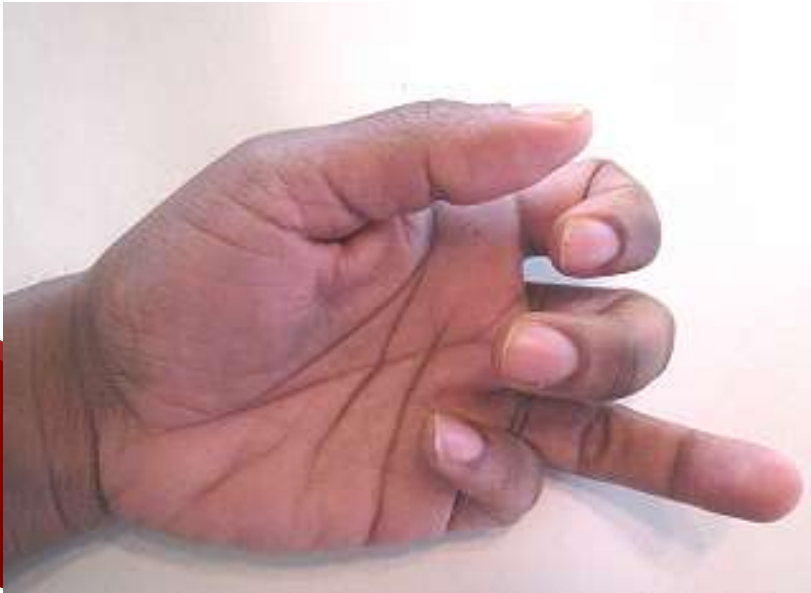

Jersey Finger

-
-
-
-



Jersey finger





- Swelling
- discoloration



-
-
-
-
-
-
-

recovery

vision

- May have weakness with gliding motion of ten

Boutonniere Deformity

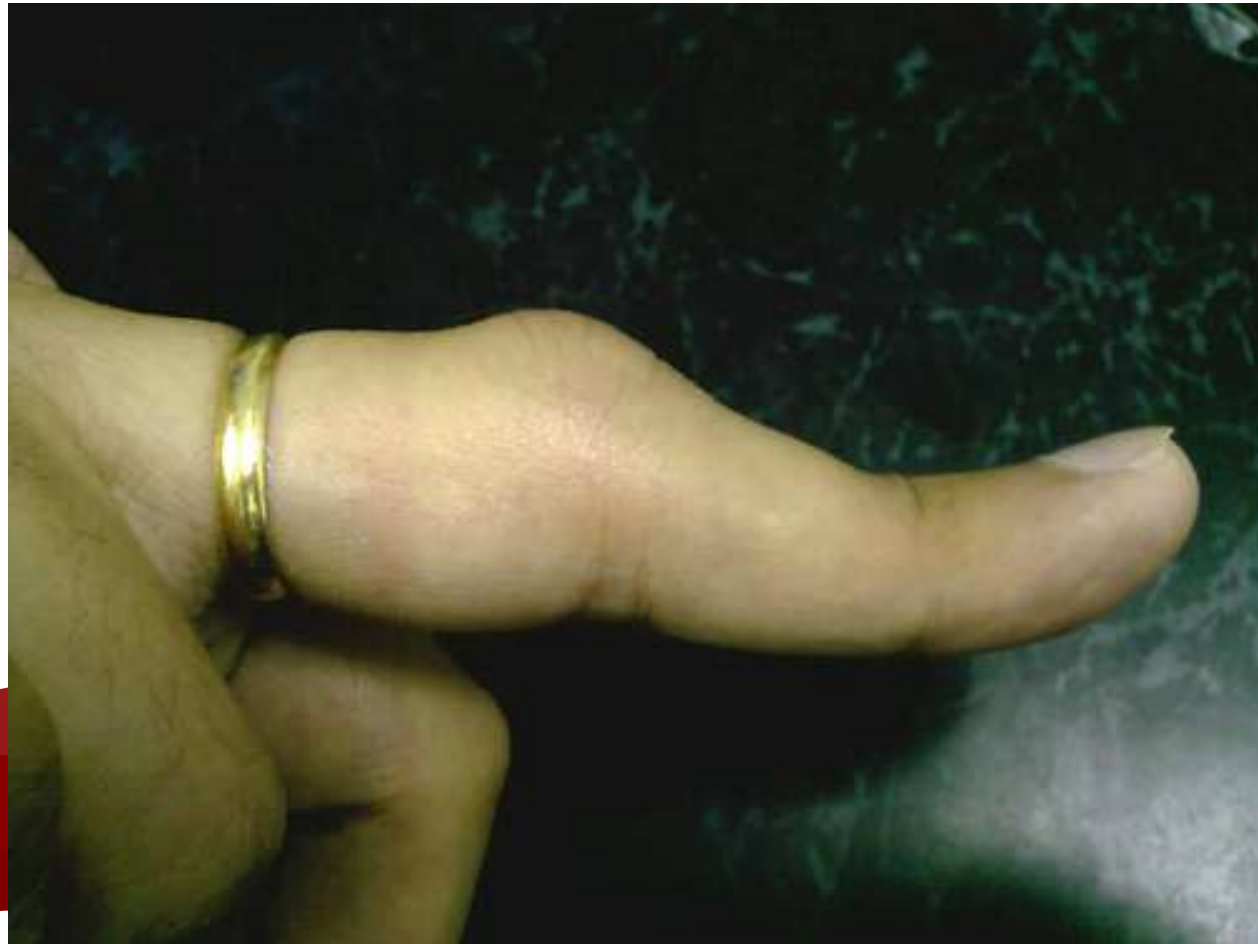-

-

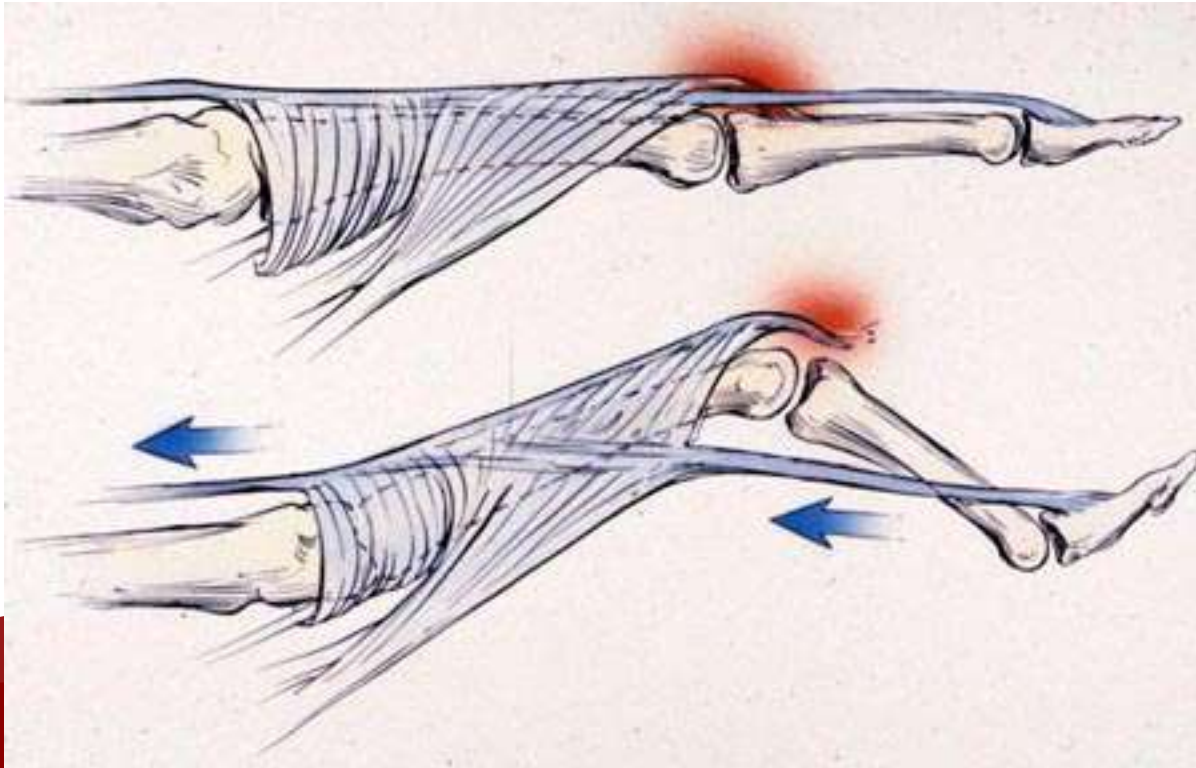
-



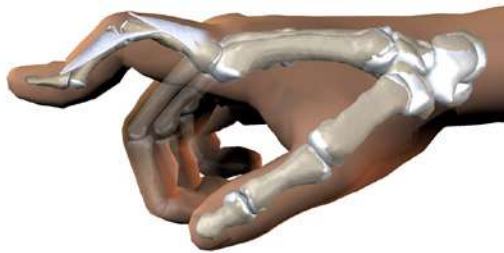Boutonniere deformity



Boutonniere deformity

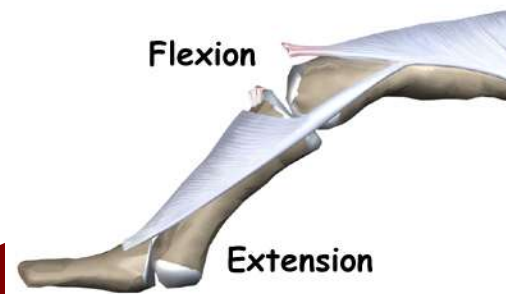


Boutonniere deformity



©MMG 2001


**Boutonniere
deformity**



Flexion

Extension

©MMG 2001




- Deformity of PIP in flexi
extension



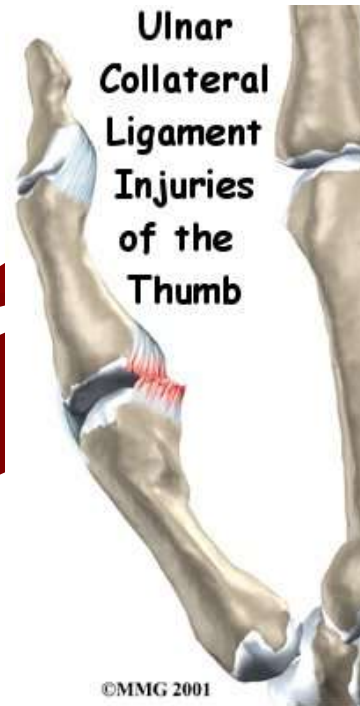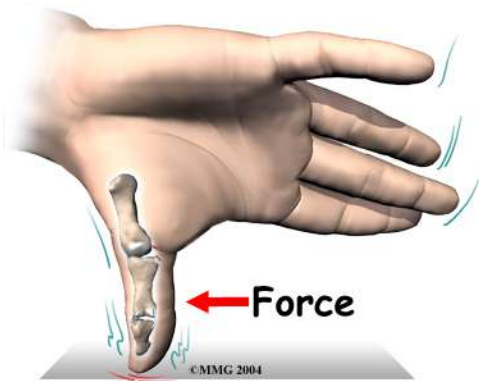
with flexion of

Gamekeeper's Thumb

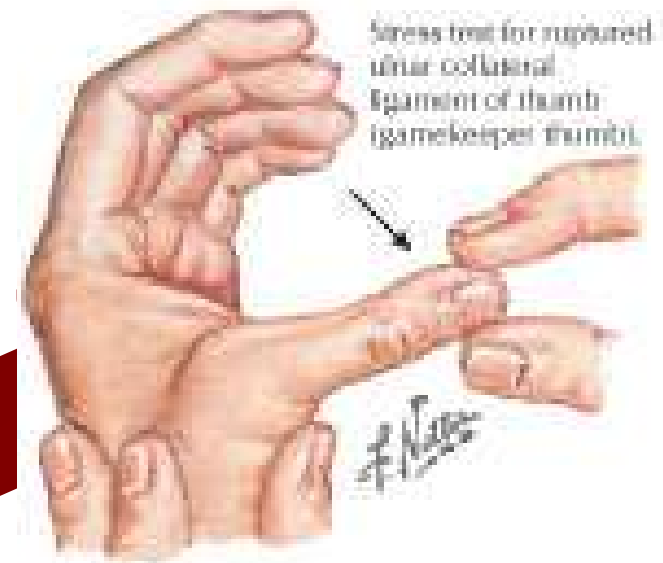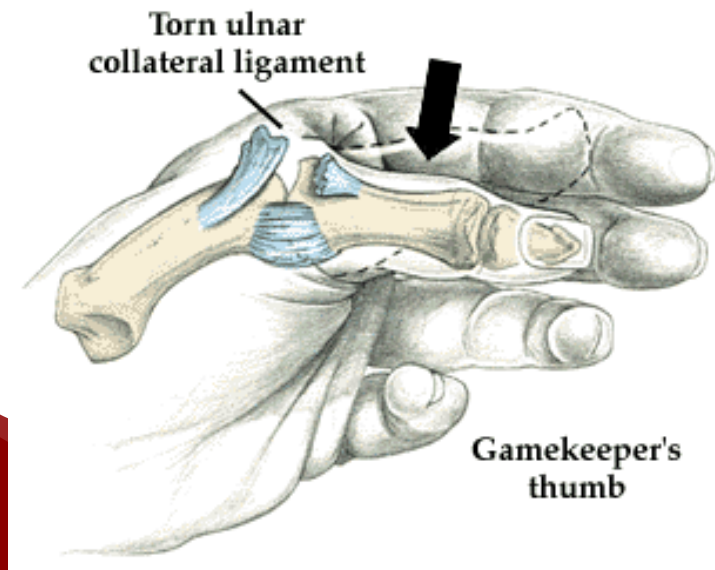
-
-
-
-



Gamekeepers thumb




Gamekeepers thumb





- Instability of joint
- Unable to grip



- Possible surgery

rule out avulsion

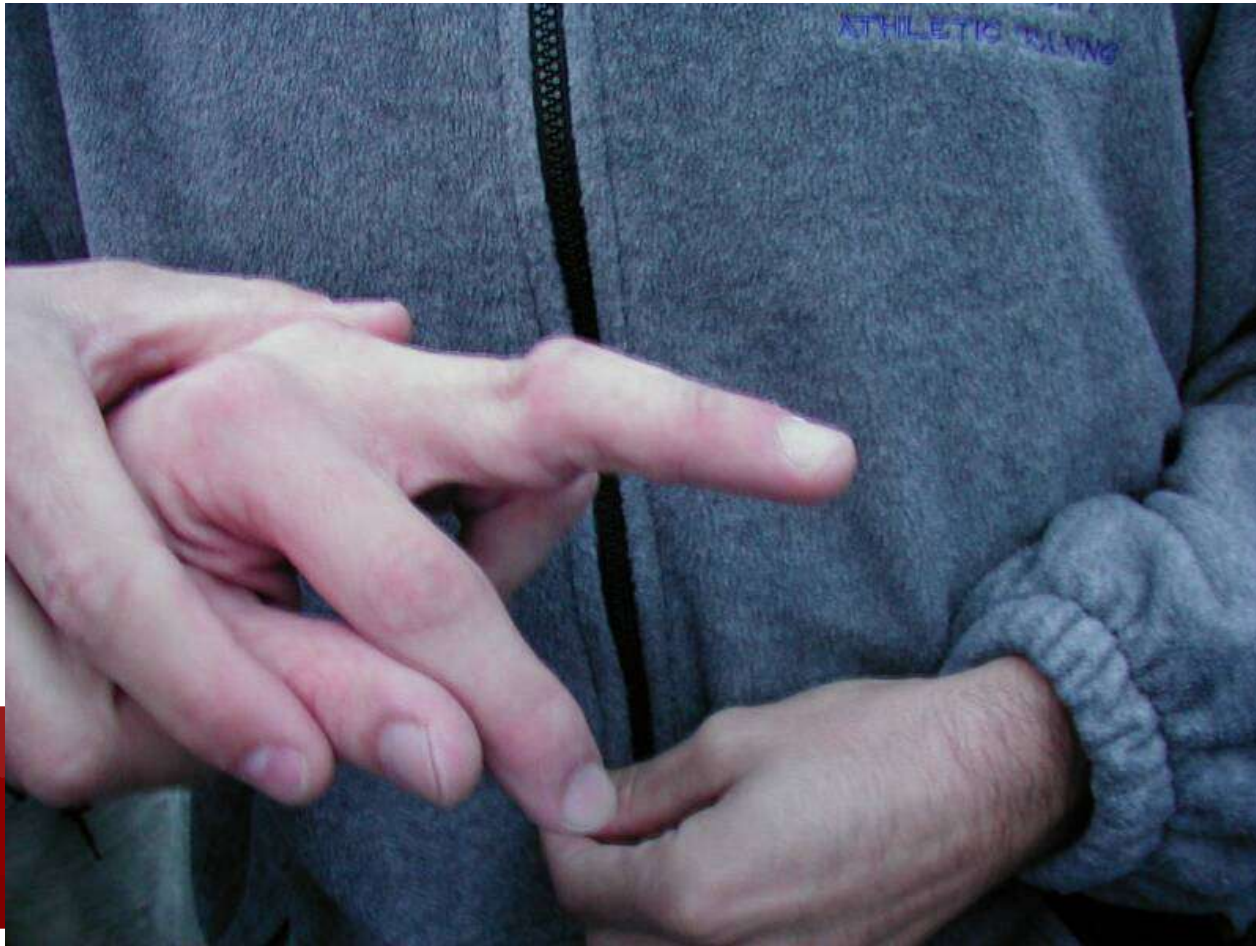Interphalangeal Dislocation

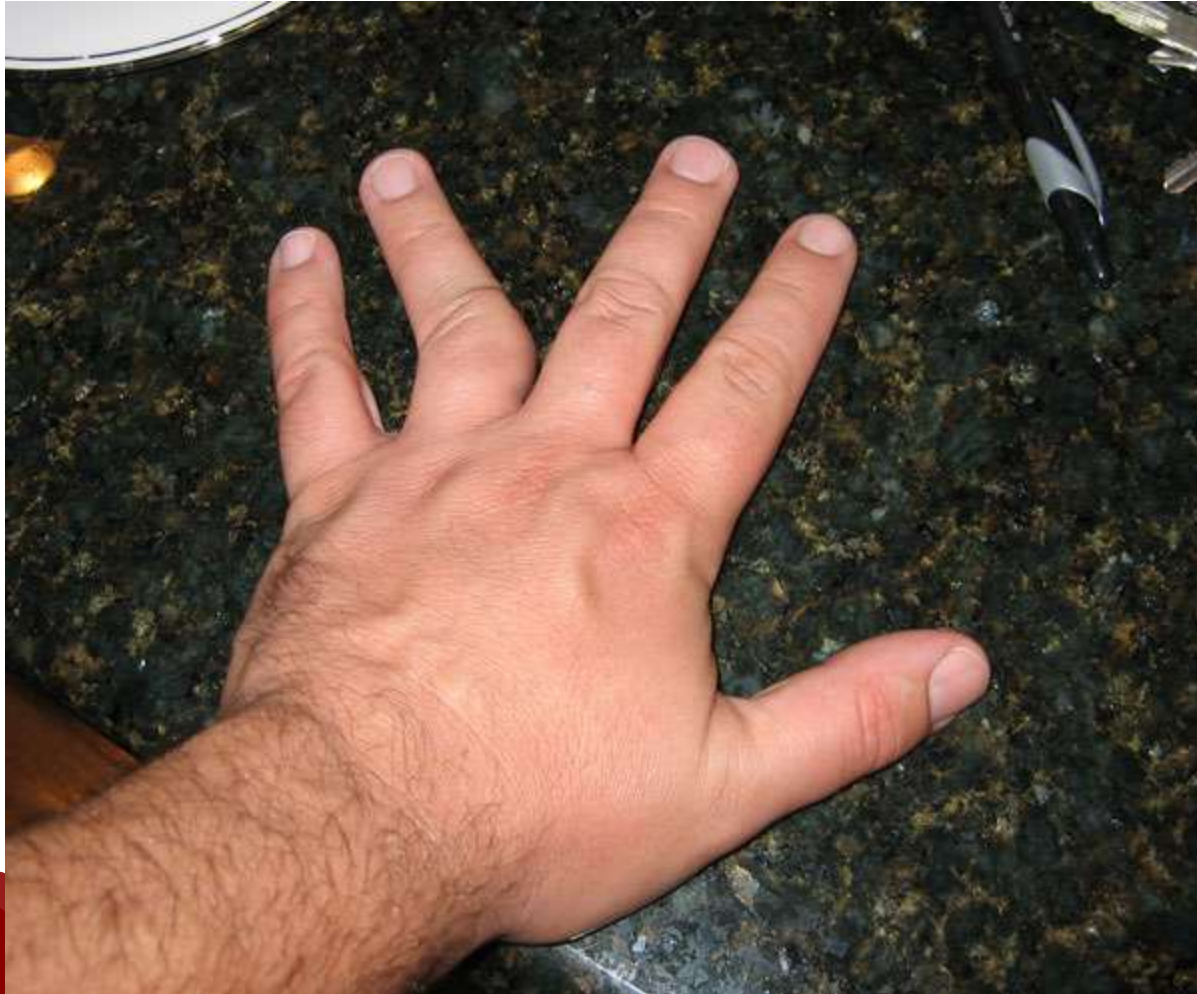-
-
-
-



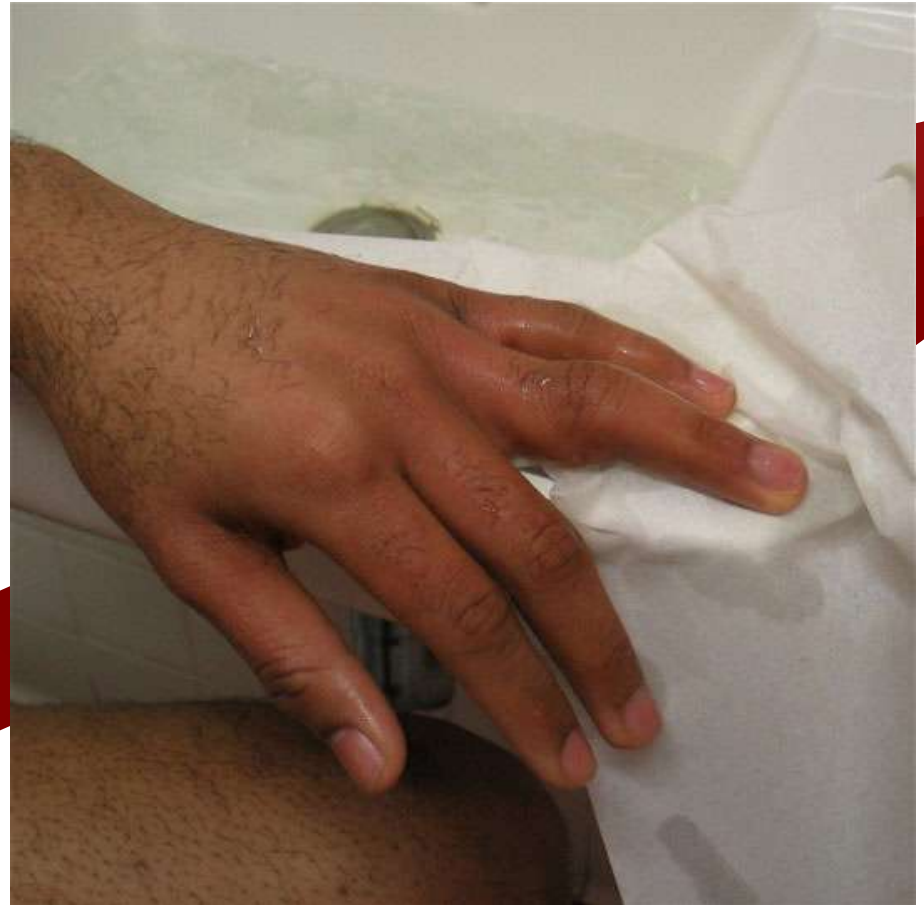Proximal phalanx, middle phalanx, distal phalanx

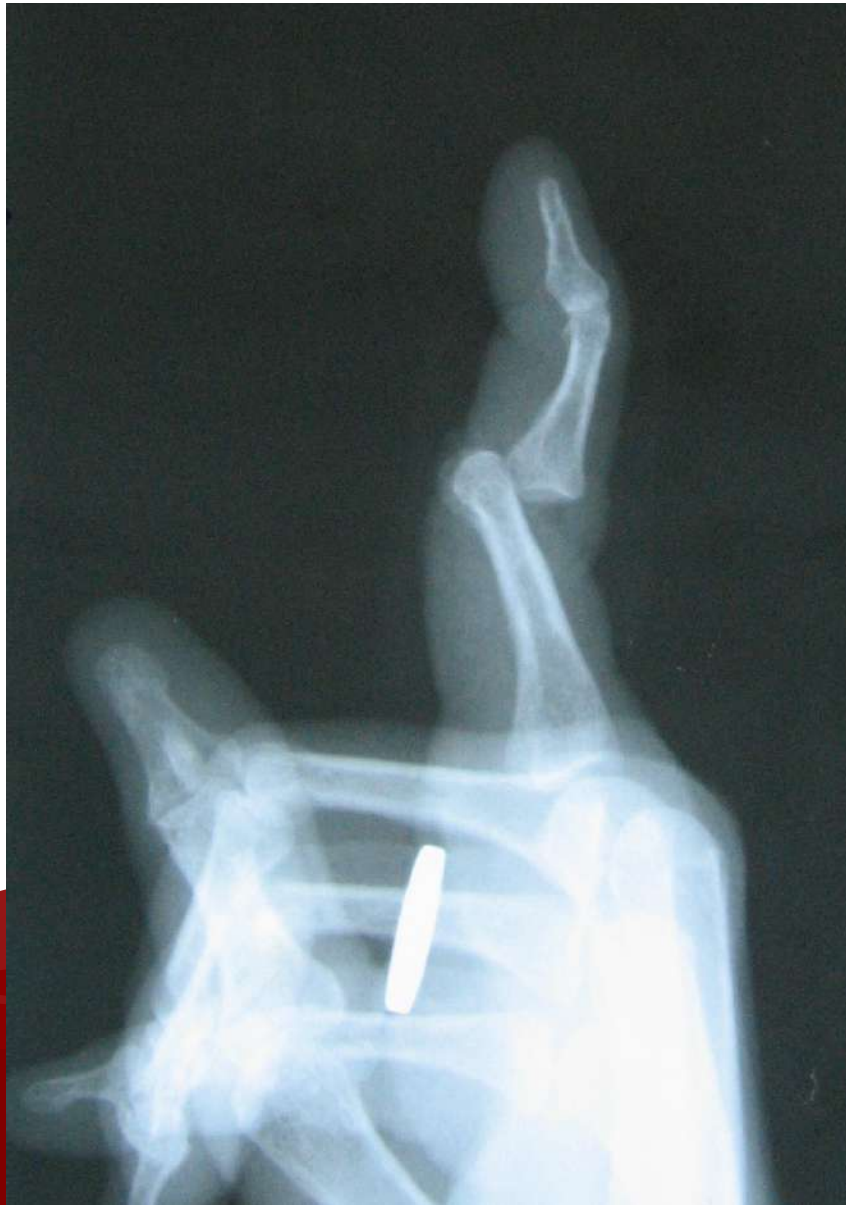
Dislocation



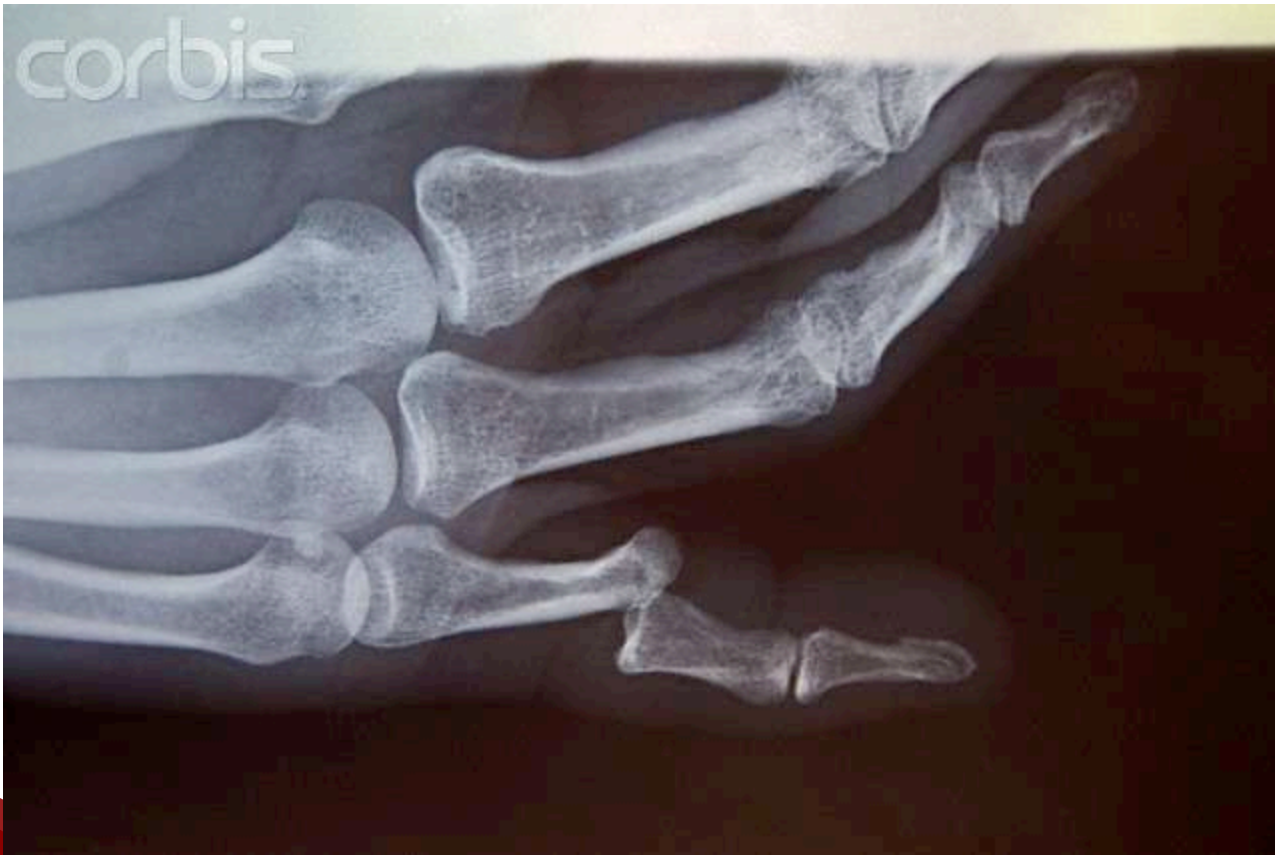


Dislocation



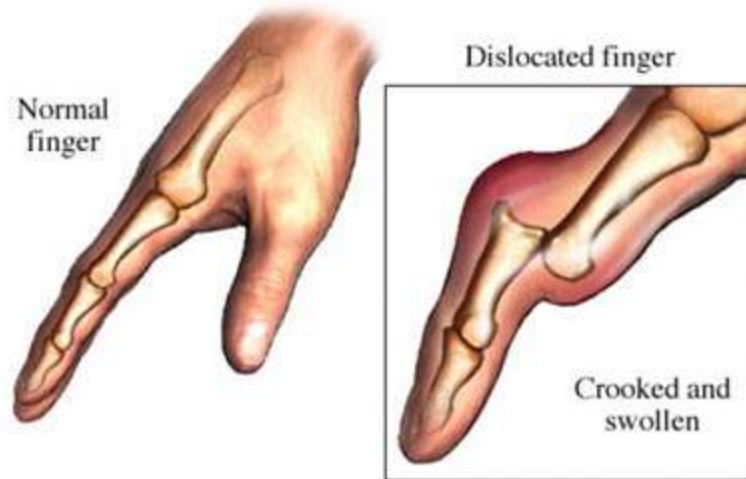


corbis

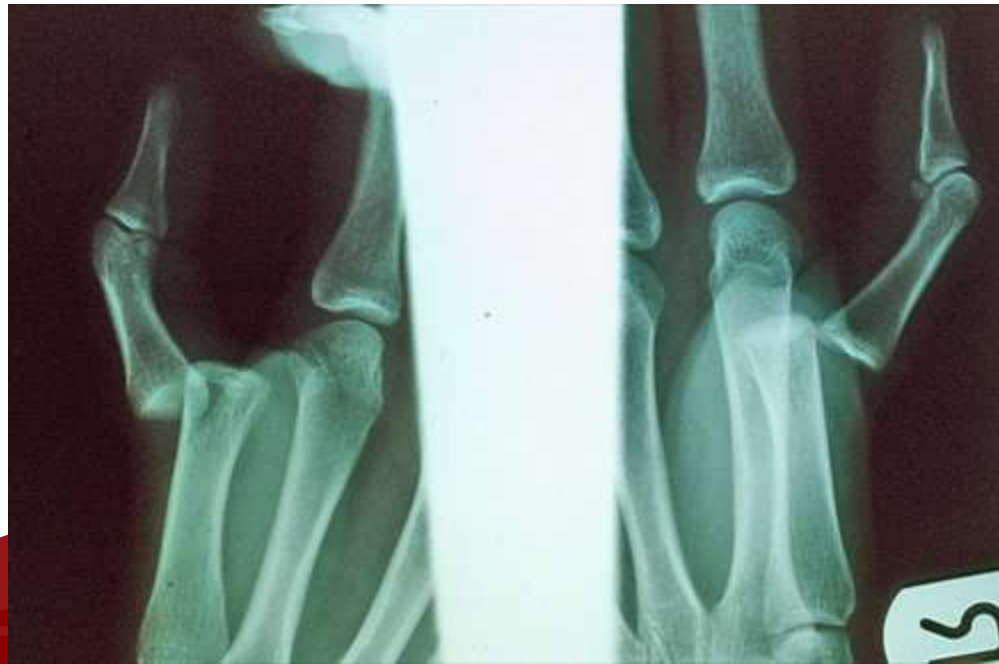




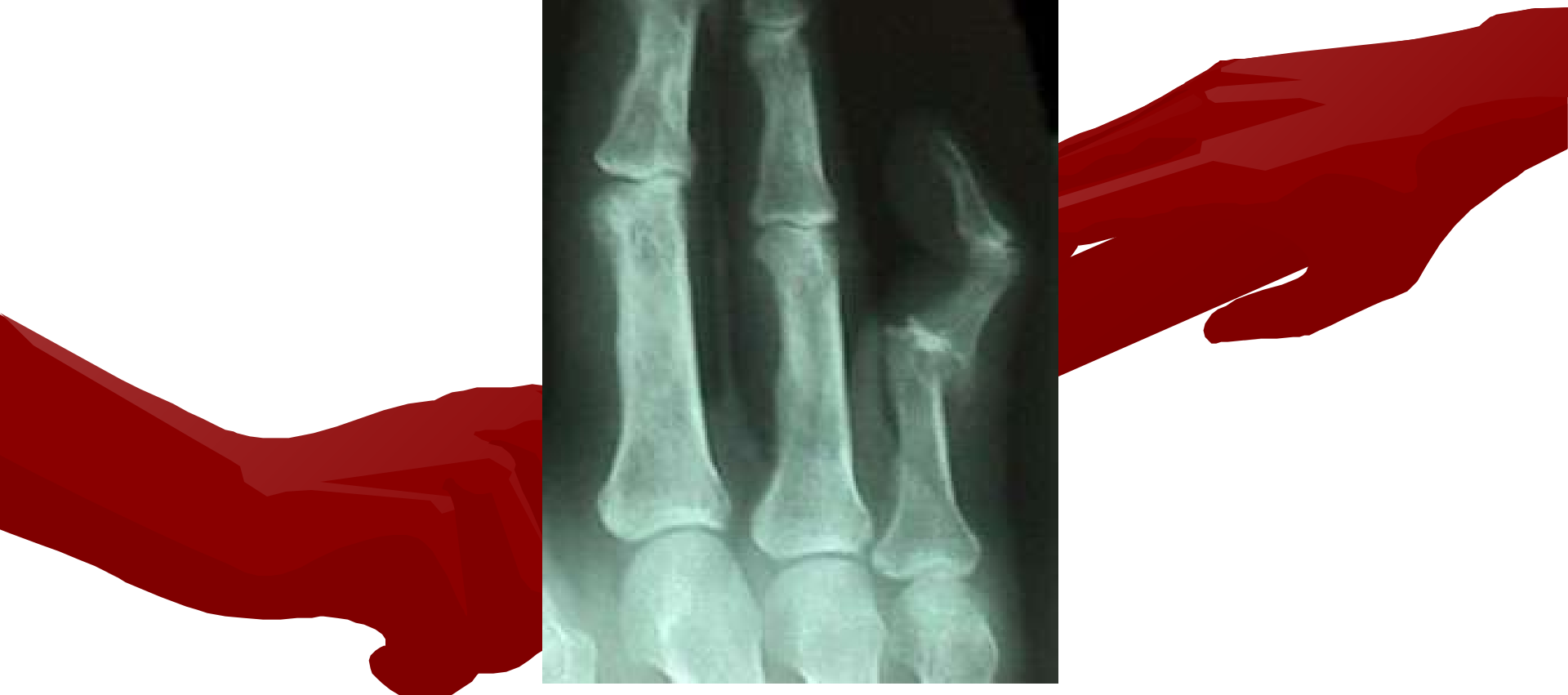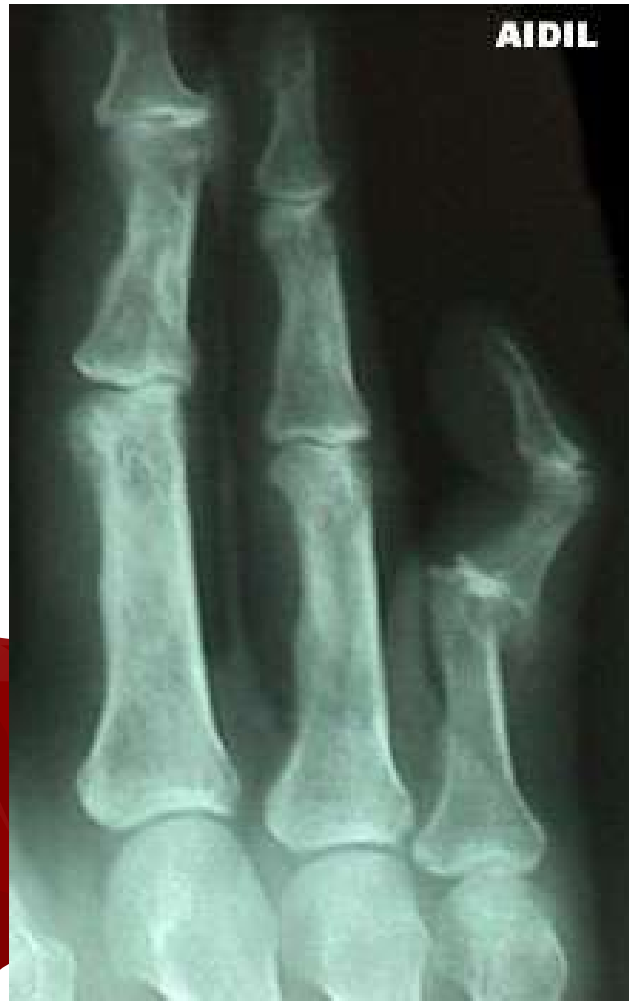Dislocation



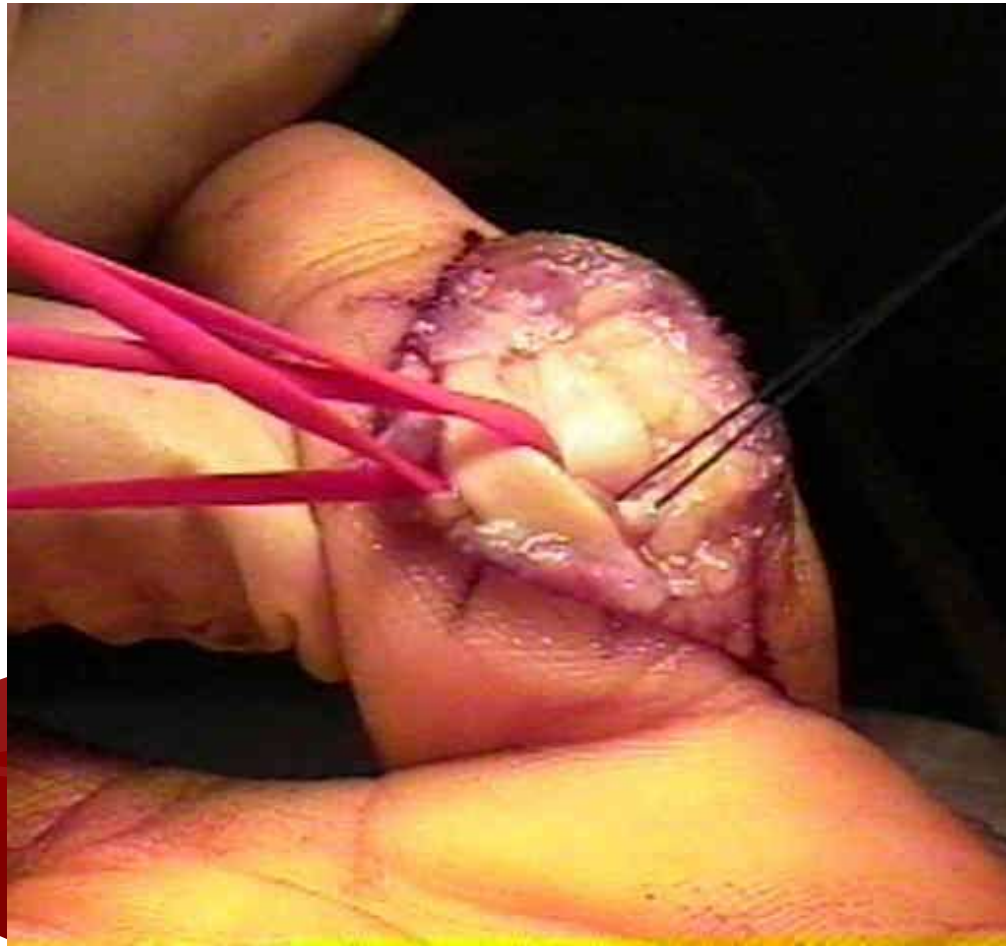
Dislocation




Dislocation




PIP dislocation



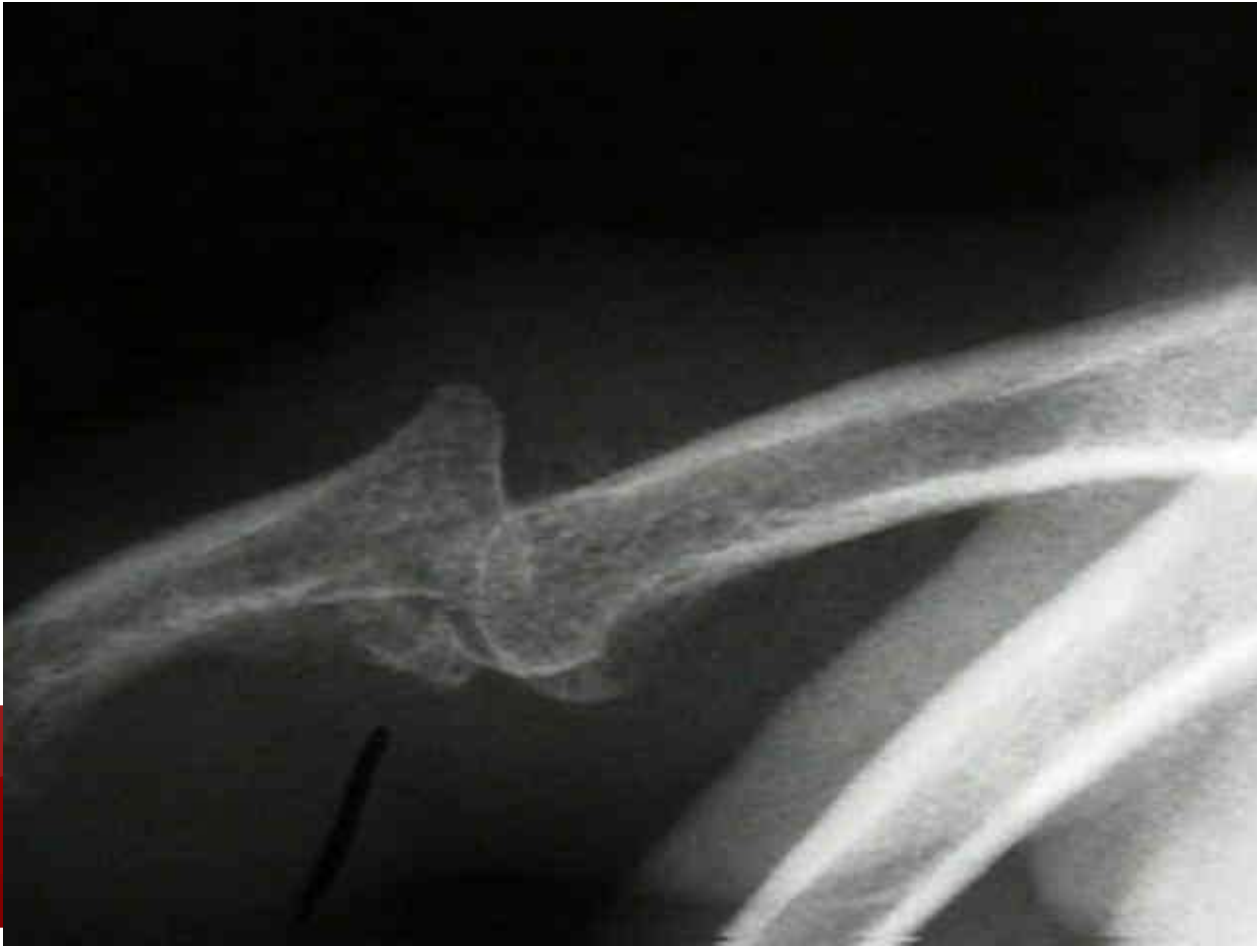

Finger fracture

-
-
-
-

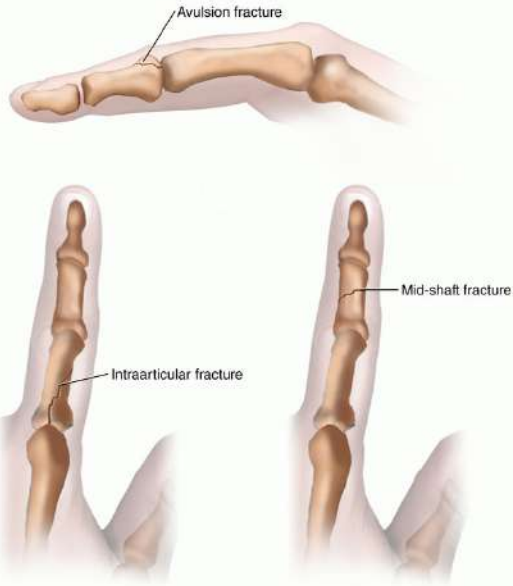

Fracture

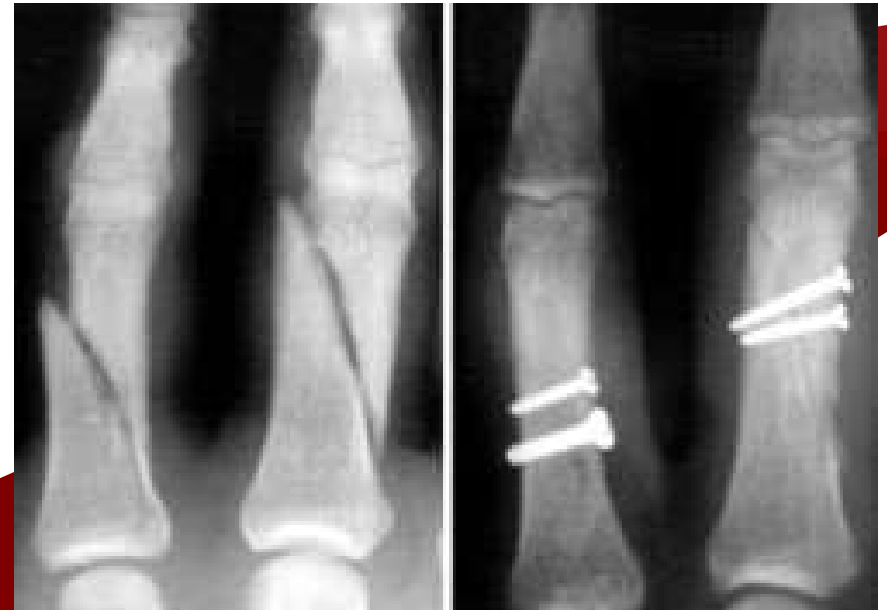

Fracture

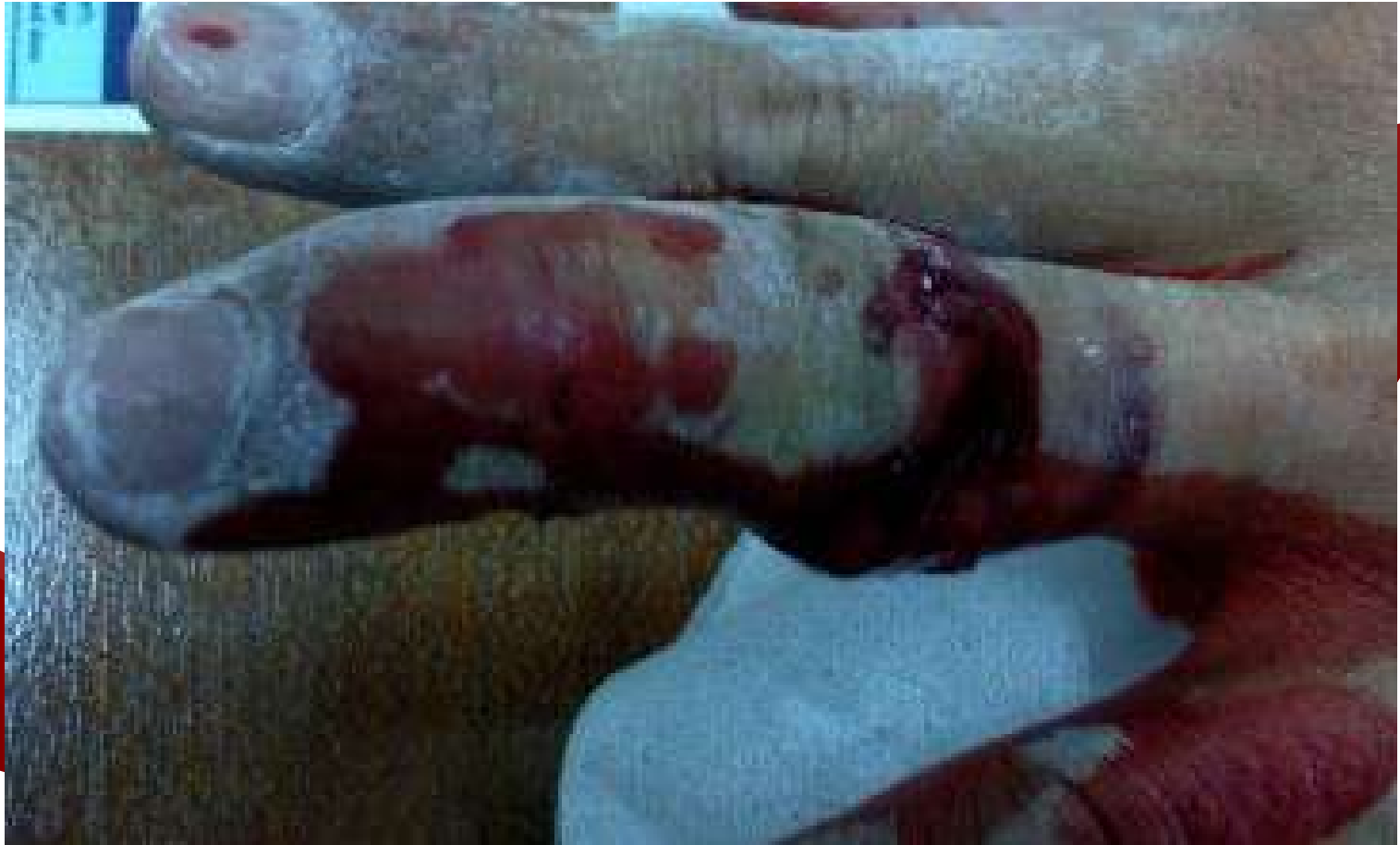Finger Fracture



© 2007 RelayHealth and/or its affiliates. All rights reserved.




Finger fracture






- POT
- + compression/perc

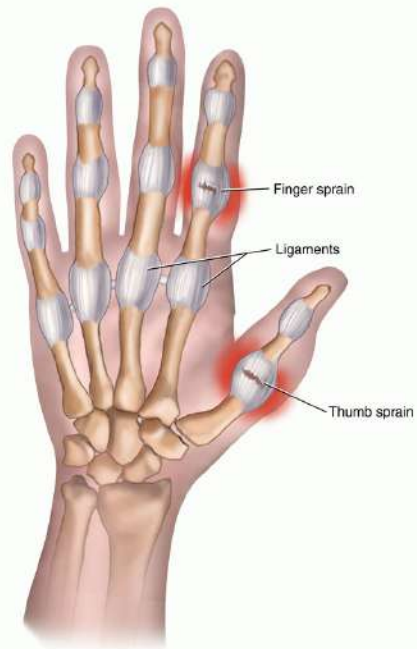

Finger Sprain




Sprain

Finger and Thumb Sprain



© 2007 RelayHealth and/or its affiliates. All rights reserved.




Sprain



Jammed Finger



- Joint instability

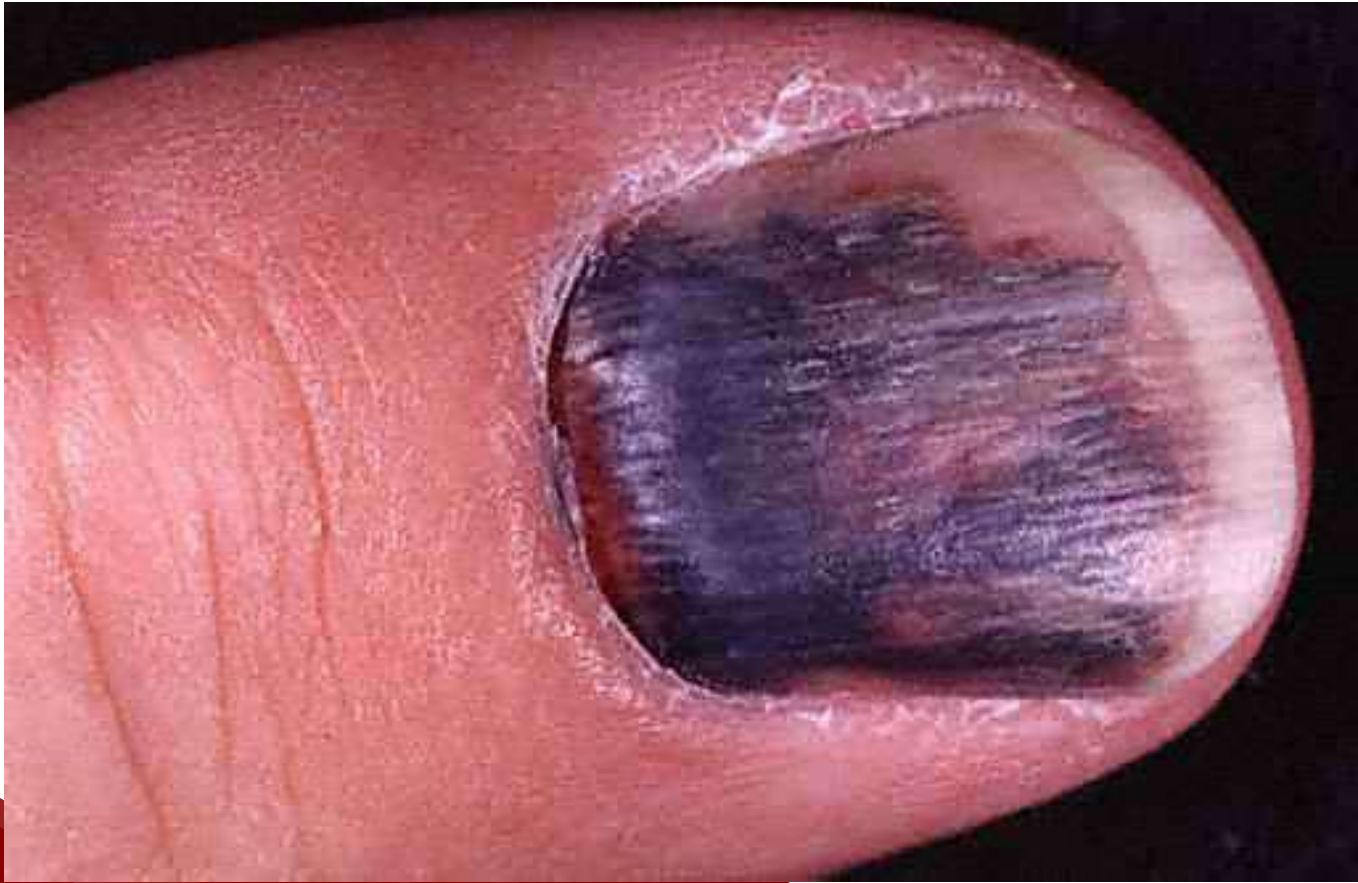


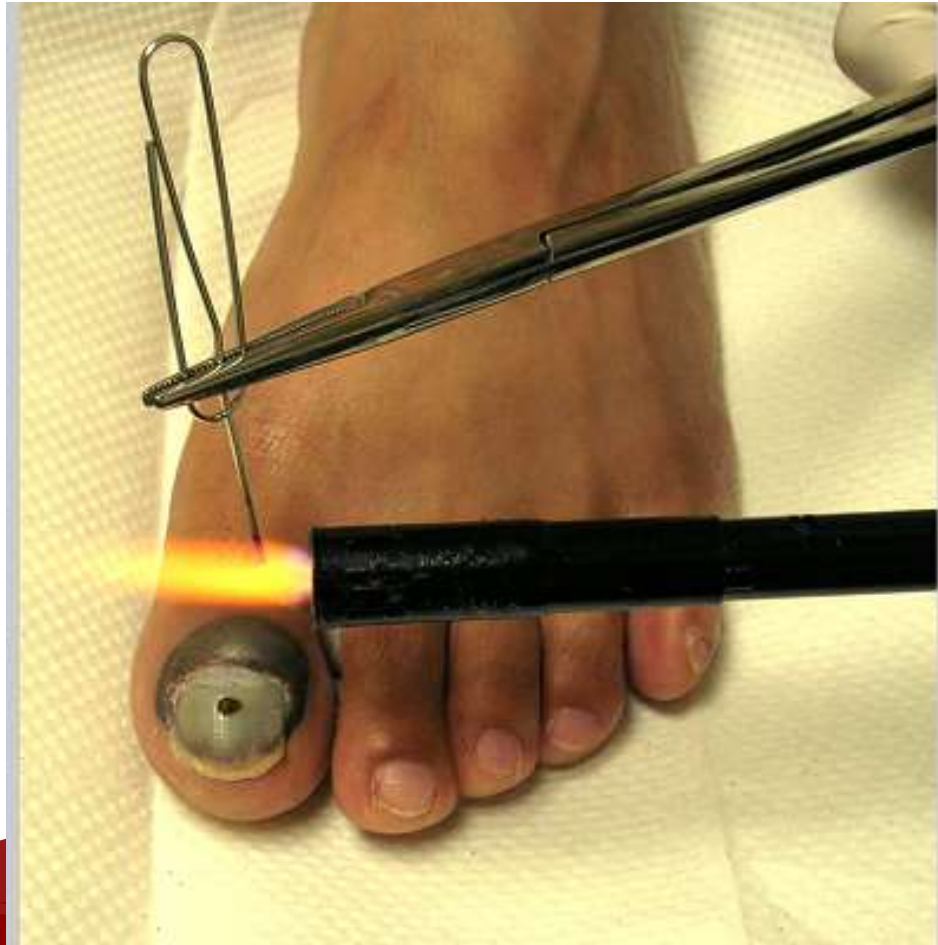
for x-rays

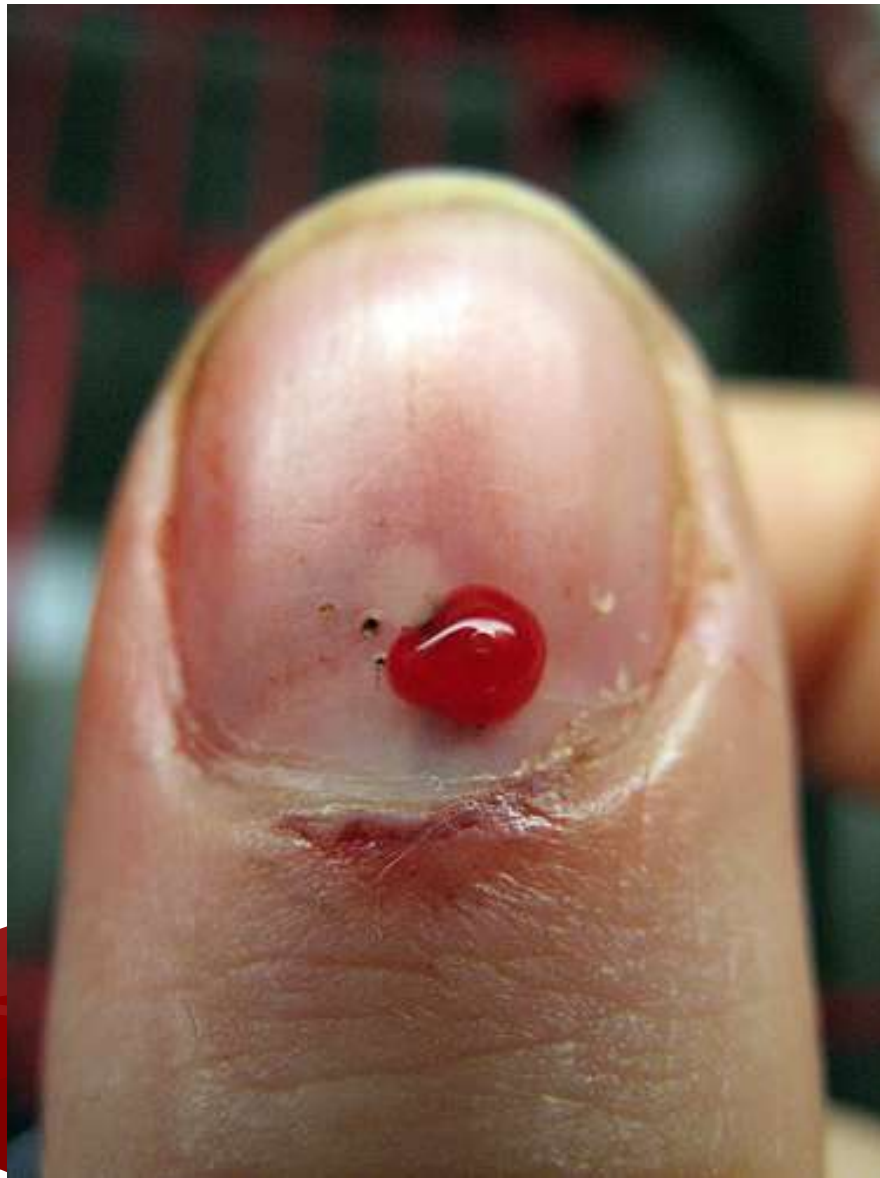

Subungual Hematoma

- Common
 - Trauma
 - Increase pressure under nail
→ lift the nail
- 
- A 3D-style illustration of a hand in a dark red color. The hand is shown from the side, with the fingers slightly curled. The thumb is pointing downwards. The index finger is pointing upwards and to the right. The middle, ring, and pinky fingers are also visible. The skin is a dark red color, and the nails are a lighter red. The background is white.







Ring injury

- Swelling of body part
 - Pain, numbness, tingling, cover open
 - Go to ER
- 
- A dark red, stylized illustration of a hand with a ring on the ring finger. The hand is shown from the side, with the fingers slightly curled. The ring is a simple band. The background is white. The text is overlaid on the hand.

Ring injury

